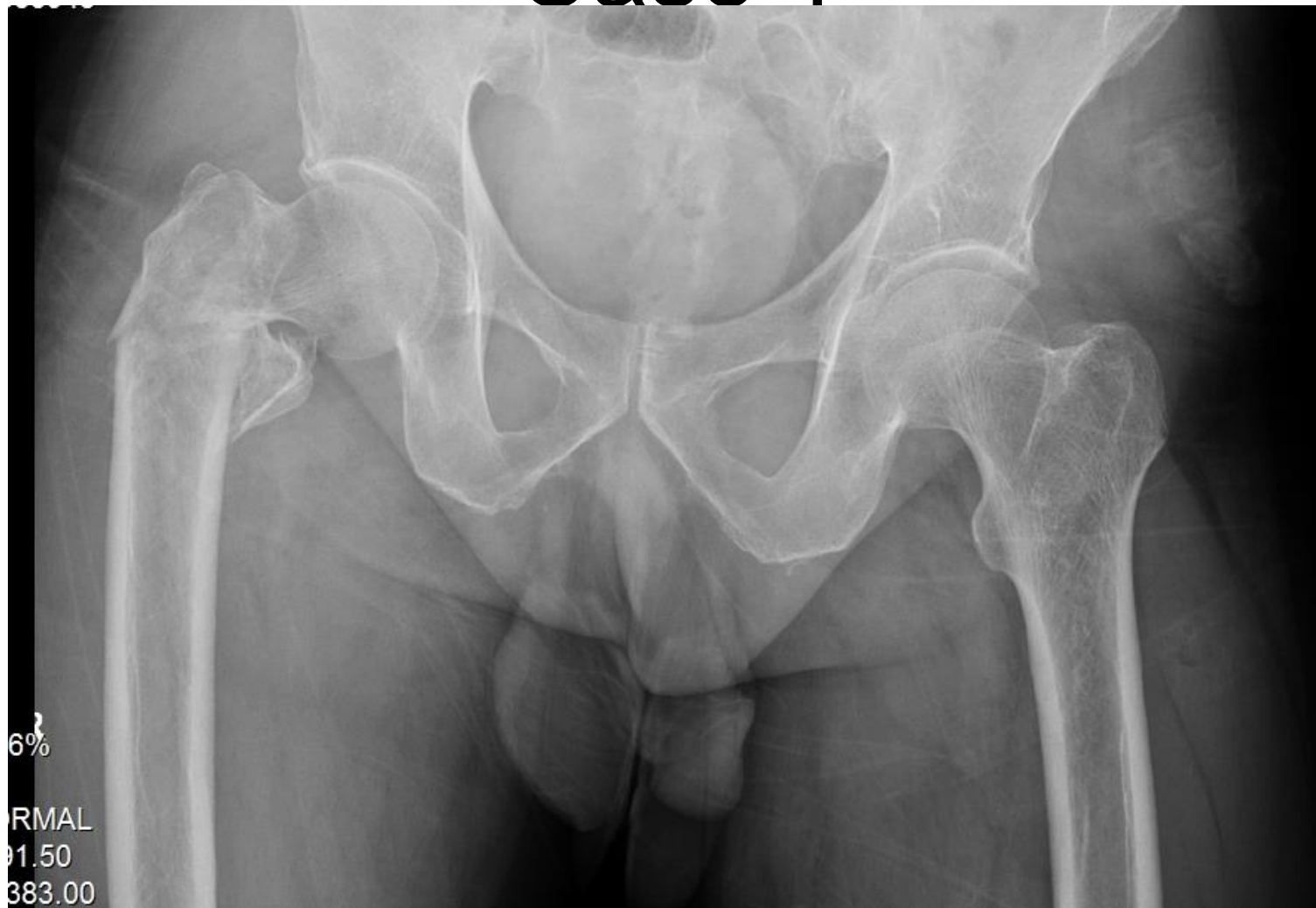


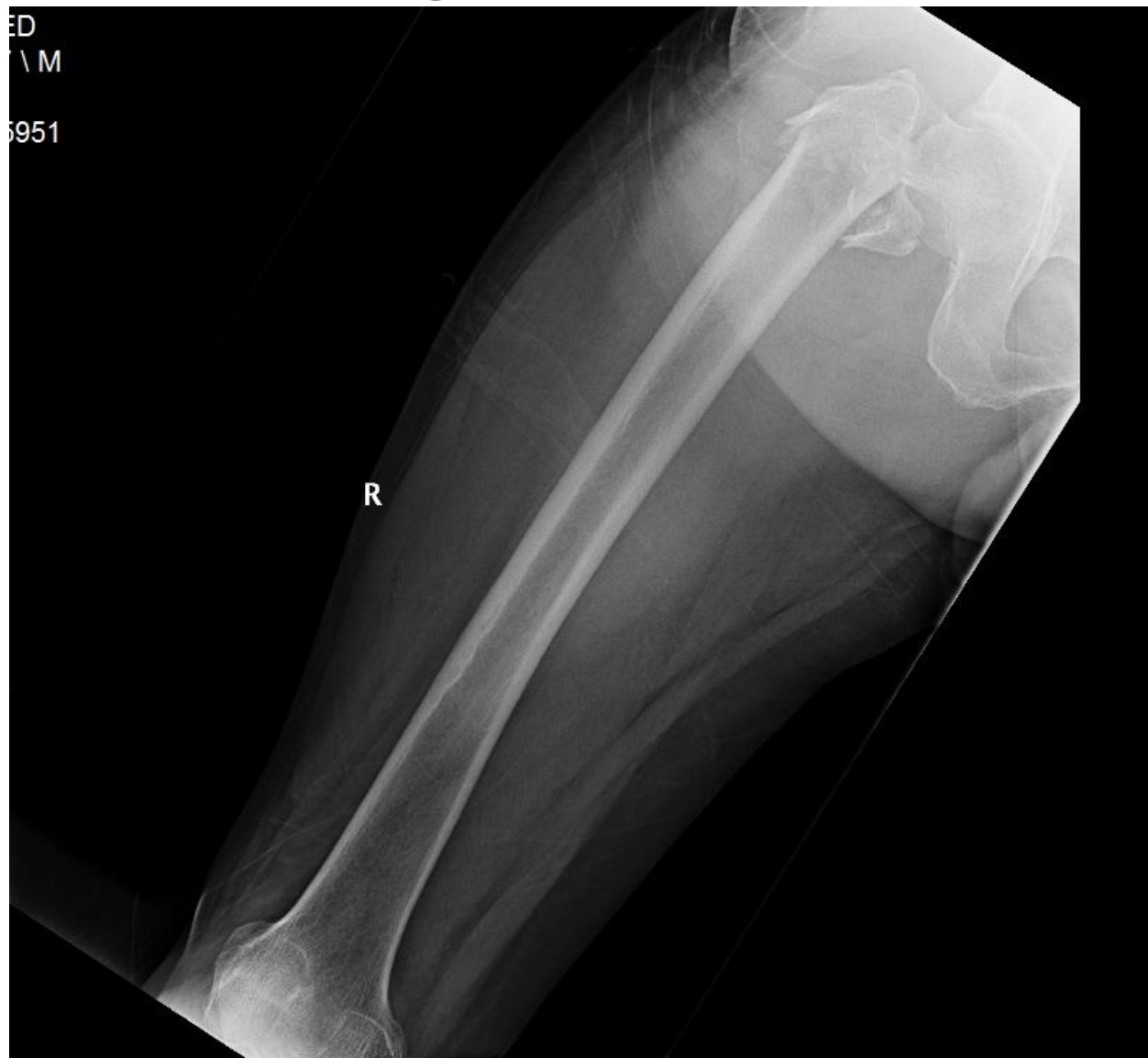CASE 1

- A 56 old male met with road traffic accident sustained injury to right hip presented in our hospital with severe inability to walk stand was diagnosed as comminuted fracture of right femur.He was operated with a PFN nail was made to walk on next day with walker support

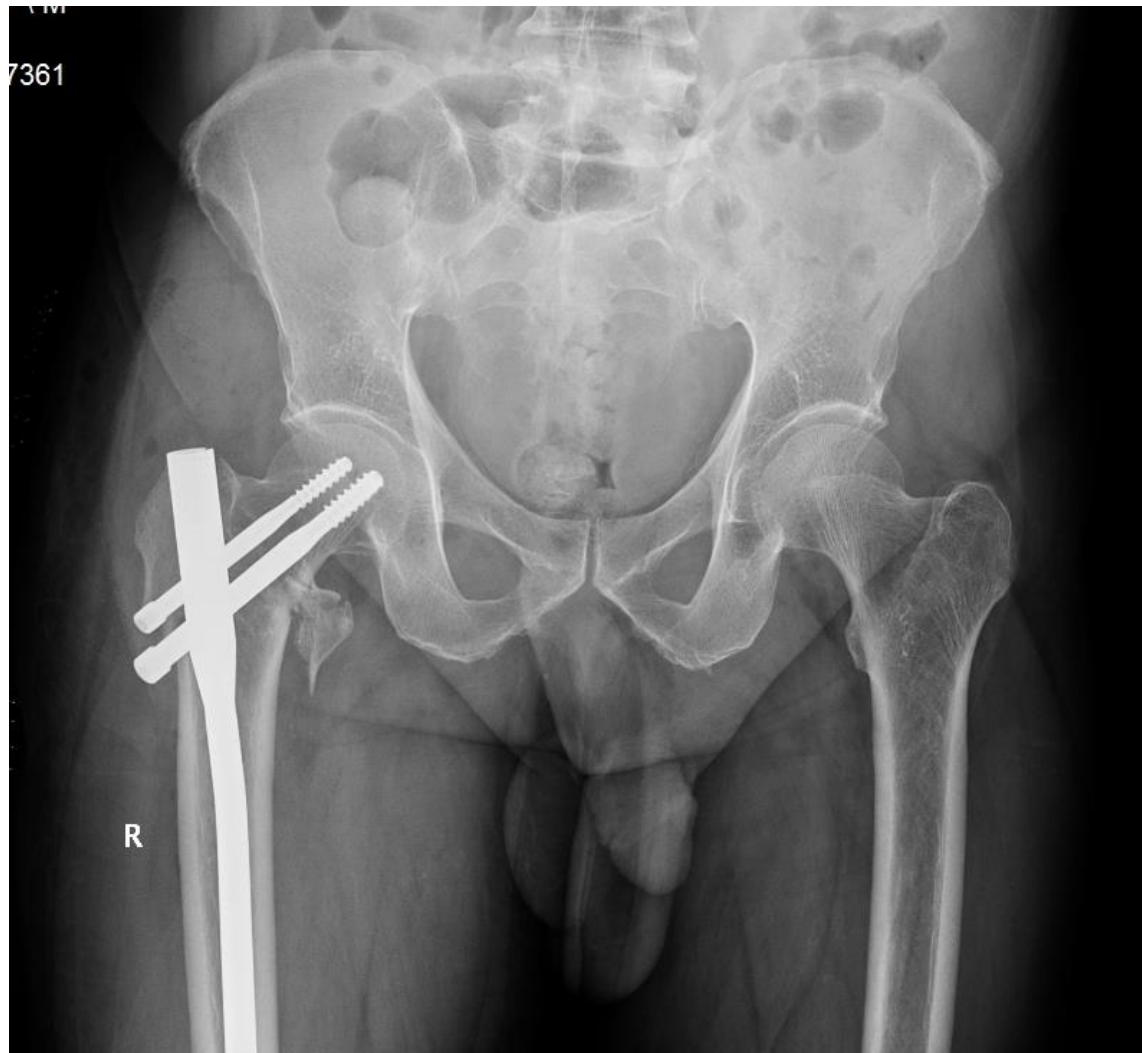Case 1



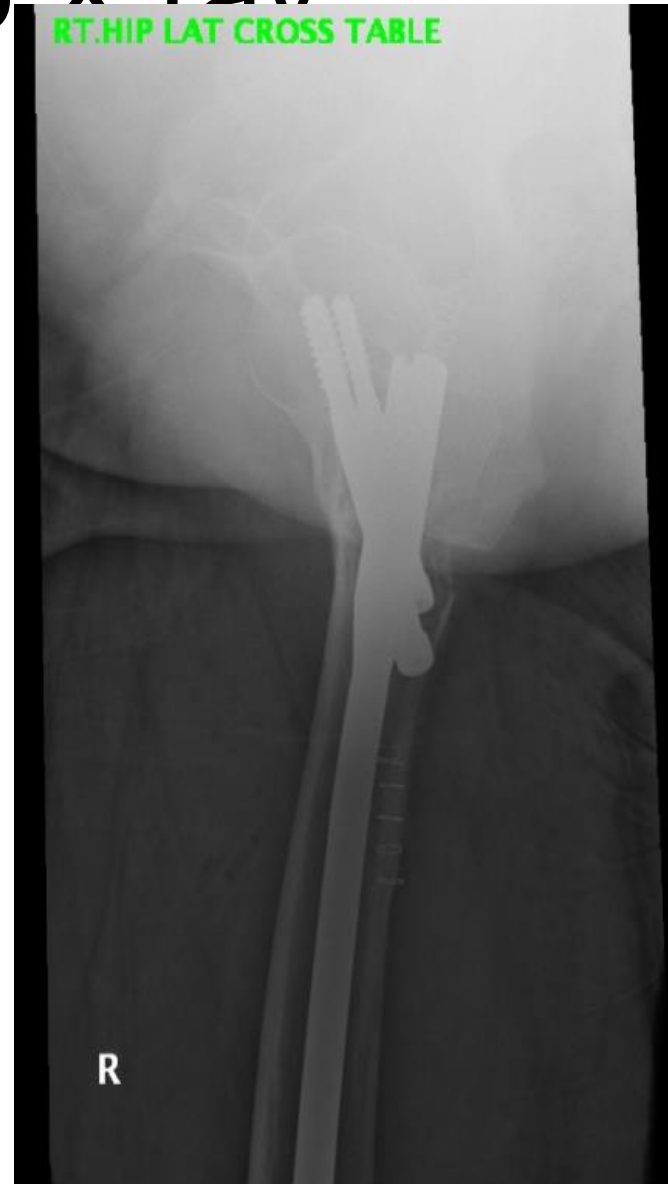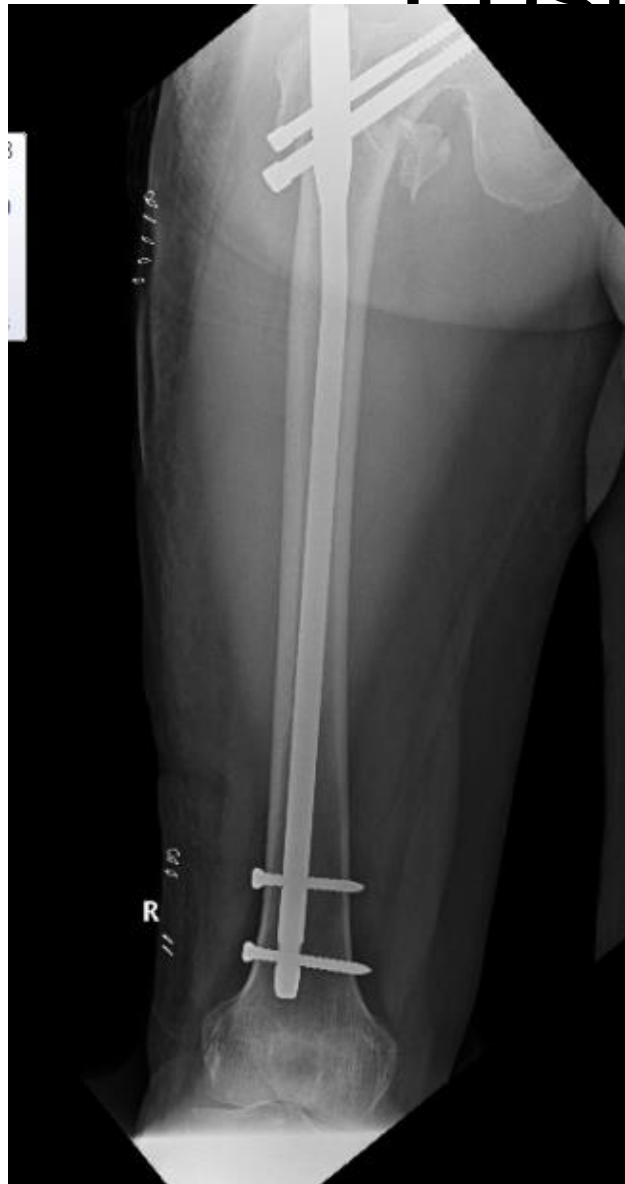Case 1



Post op X ray



Post op X ray

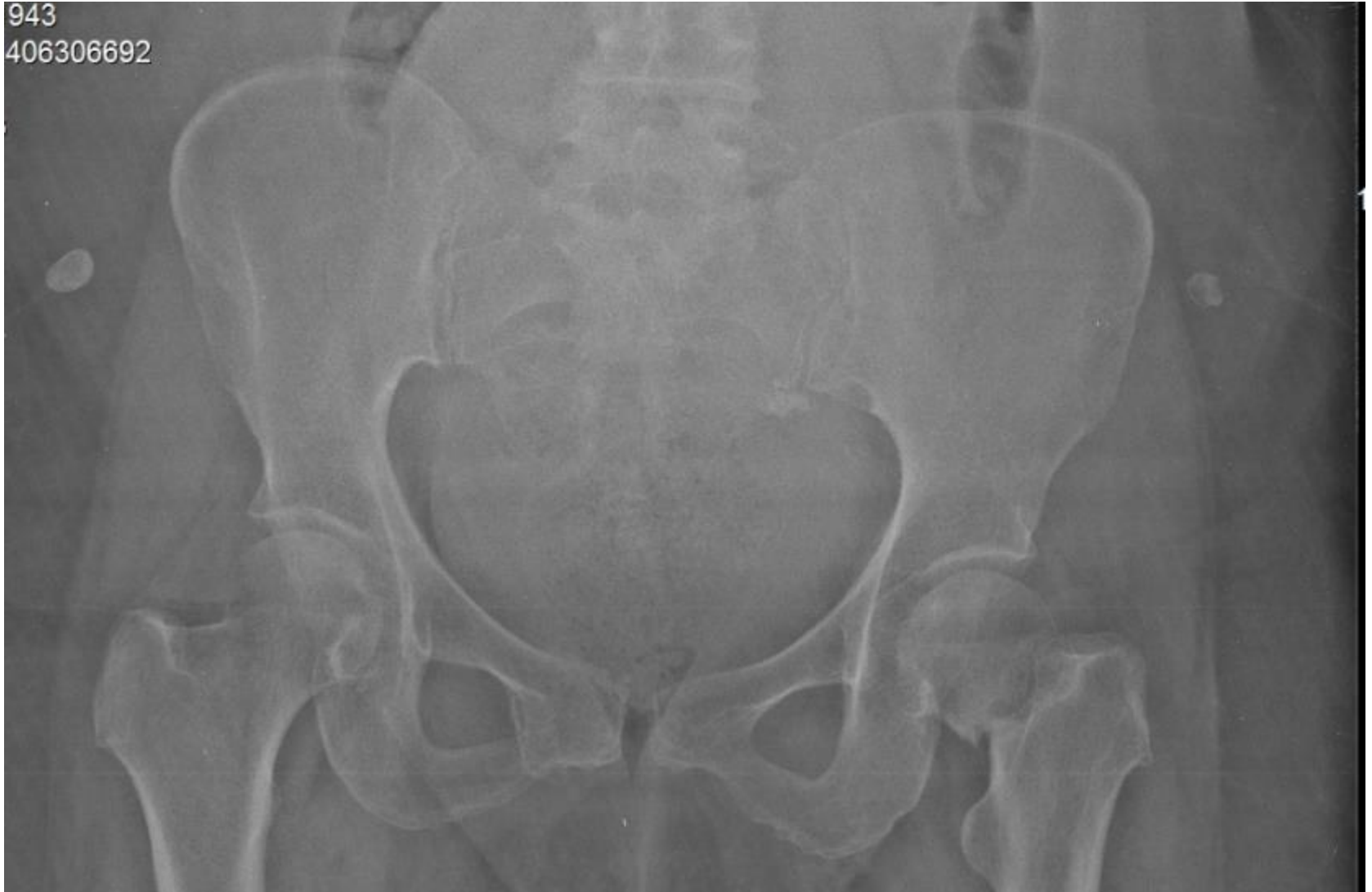

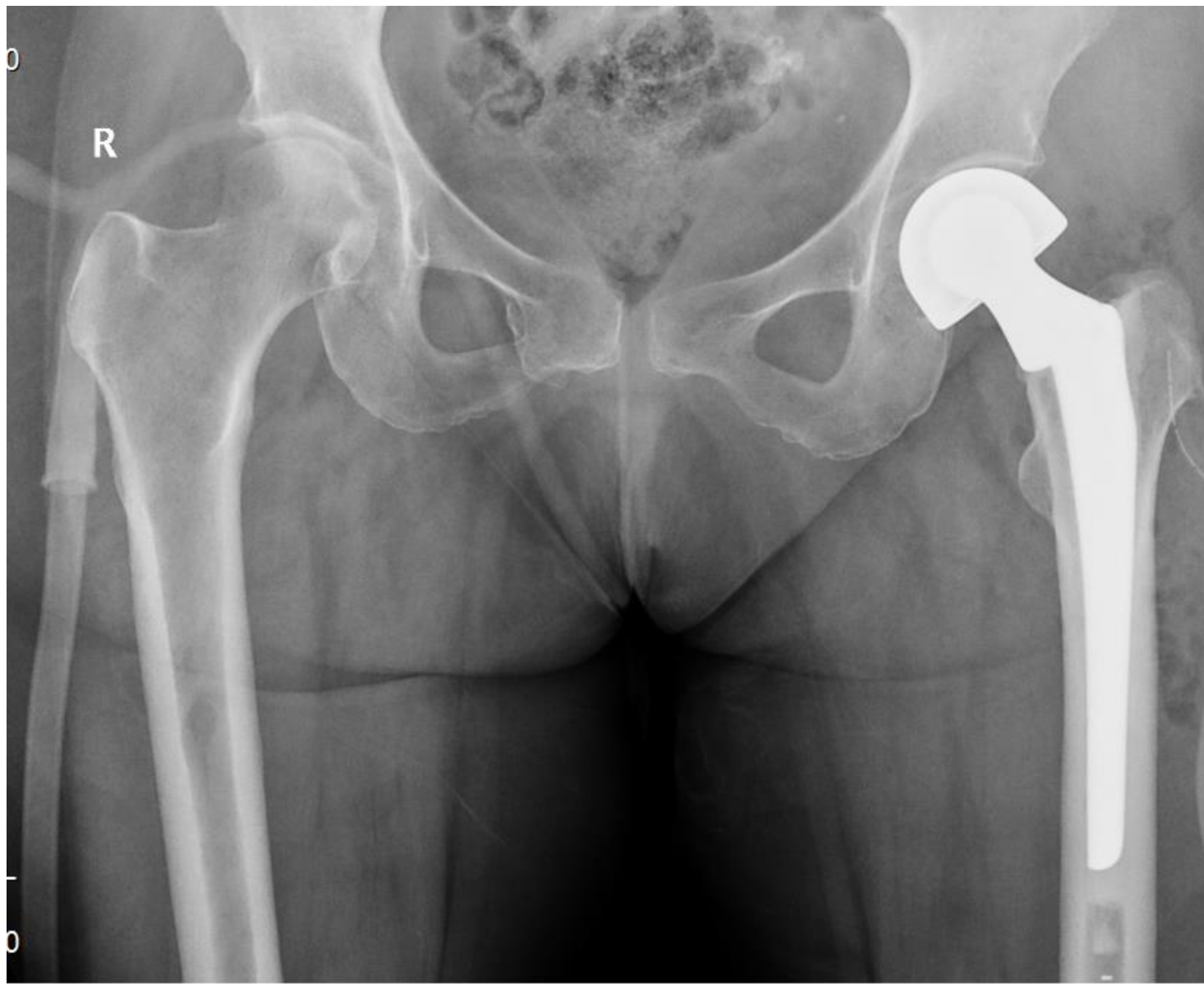
CASE 2

- A 59 old female sustained injury to left hip by having fall at home presented in our hospital with severe inability to walk stand was diagnosed as fracture neck of left femur. She was operated with Bipolar hemiarthroplasty was made to walk on next day with walker support

CASE 2

943
406306692

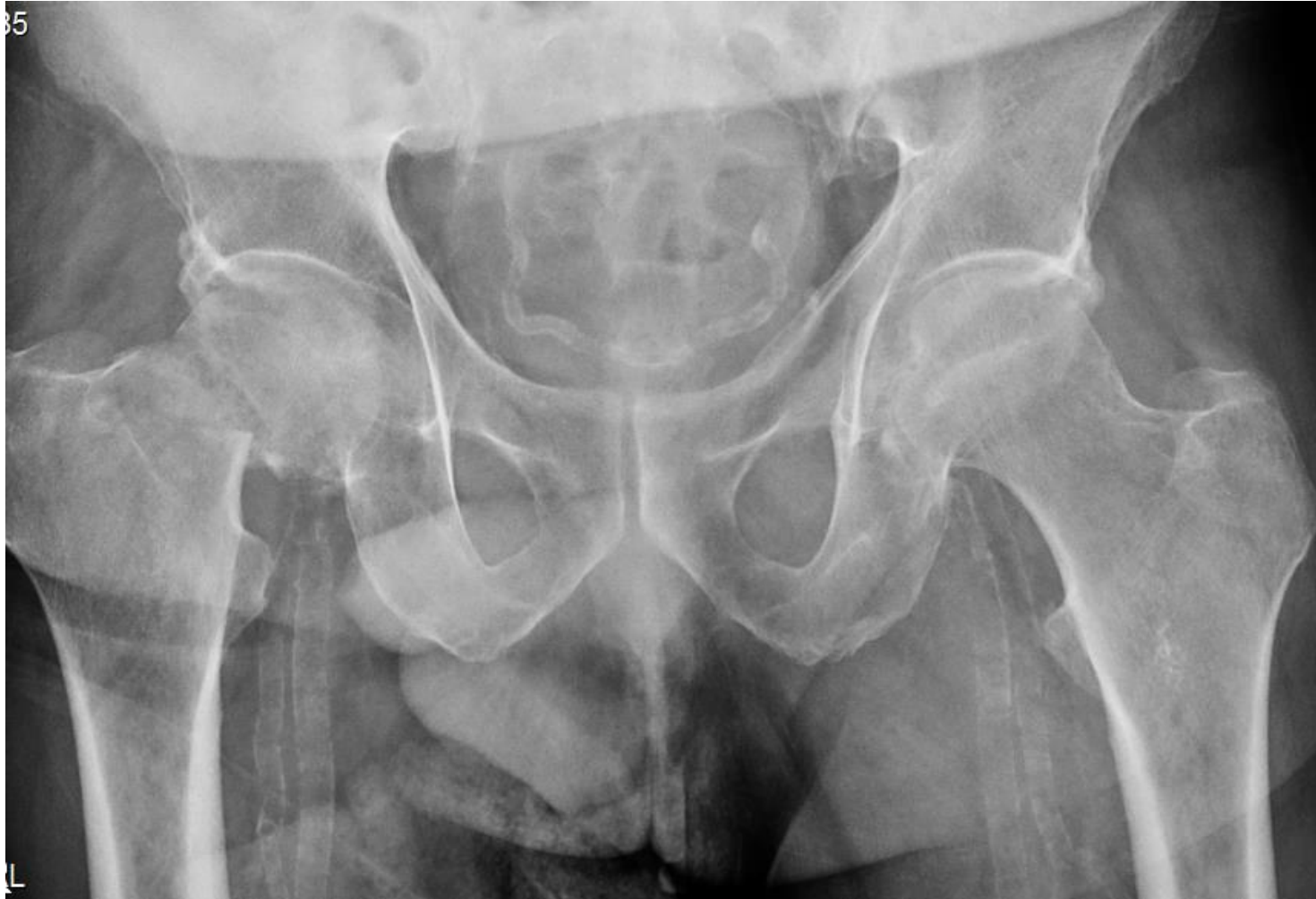



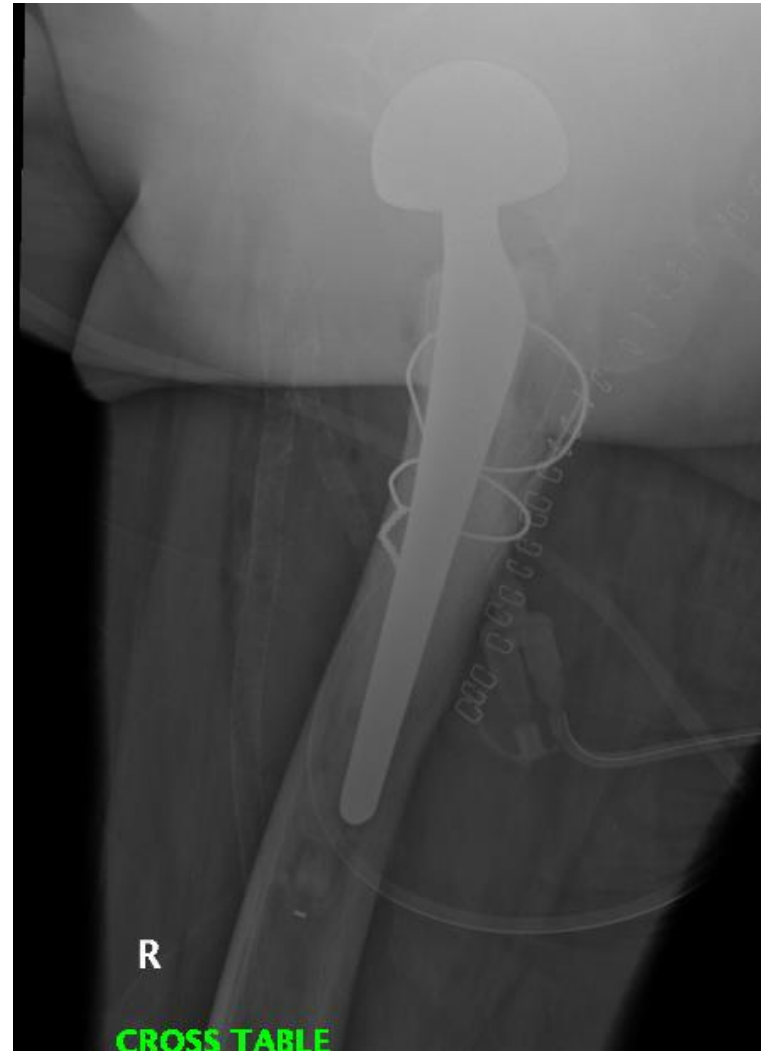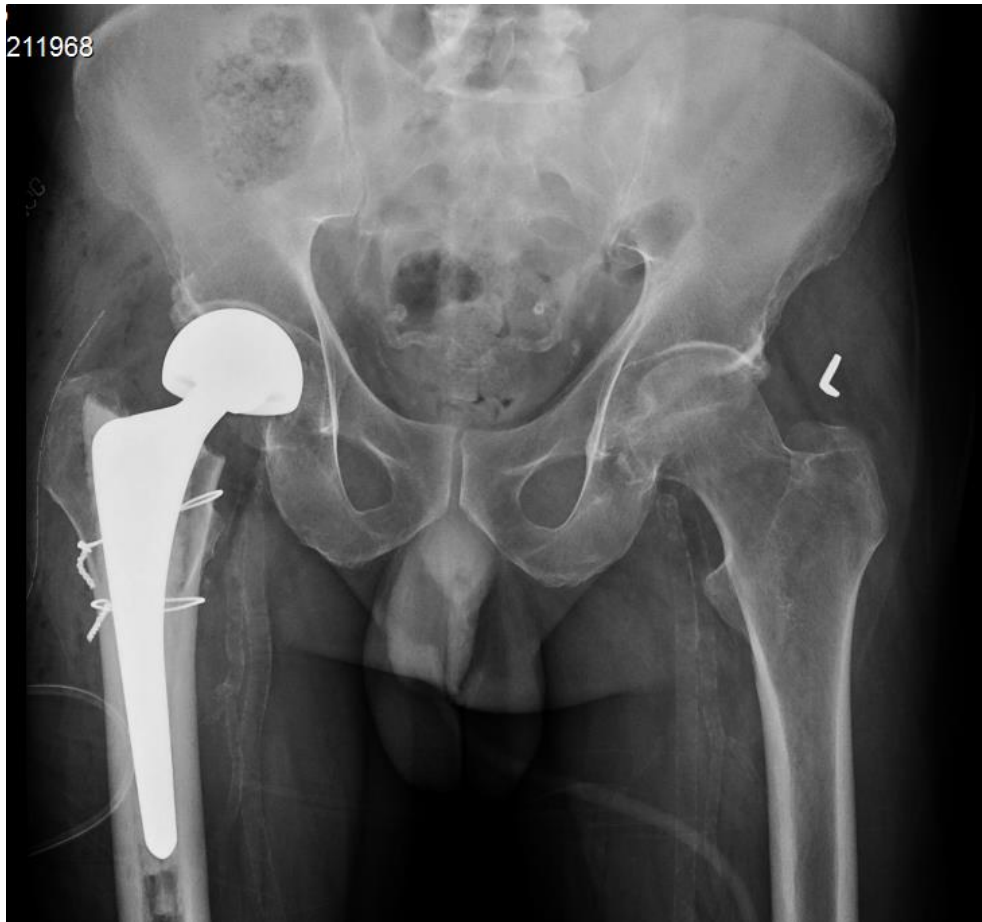
CASE 3

- A 60 yr male presented at our hospital with complain of pain in his Rt hip since 2 months following a fall at home was a known case of hemiparesis .I operated him with modular Bipolar hemiarthroplasty and made him to walk on the next day.

Case 3

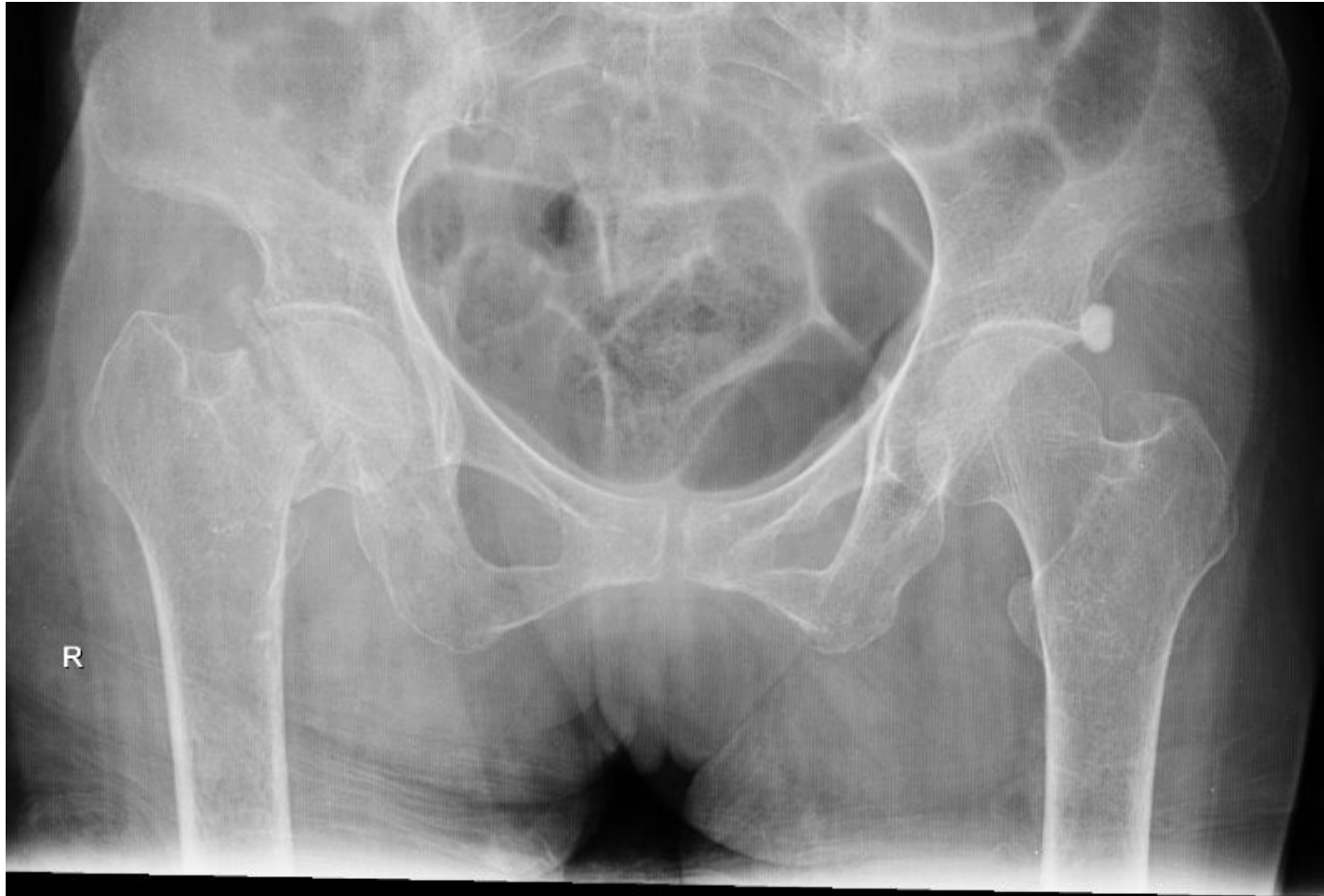

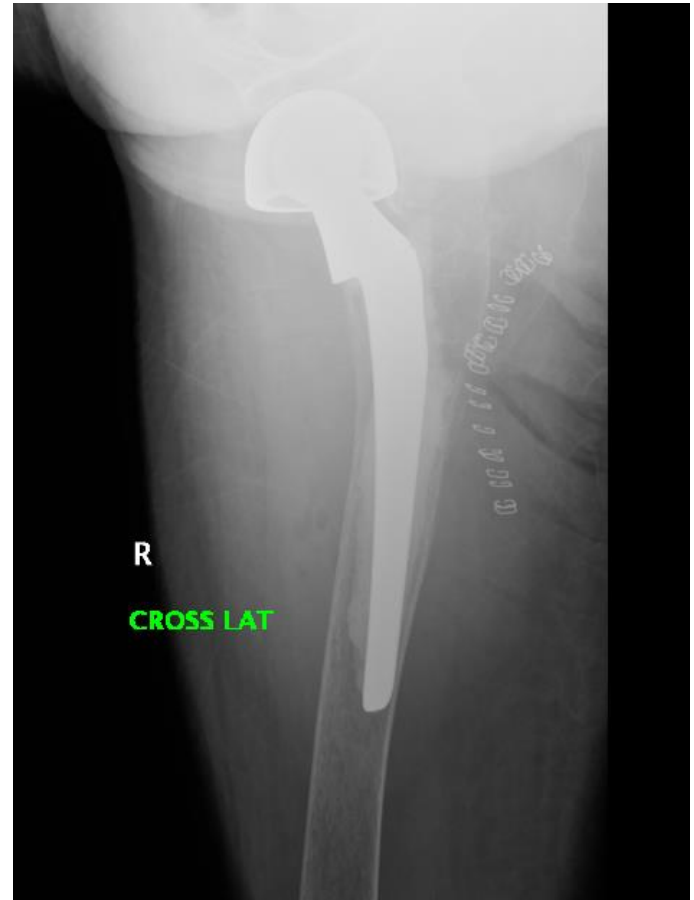
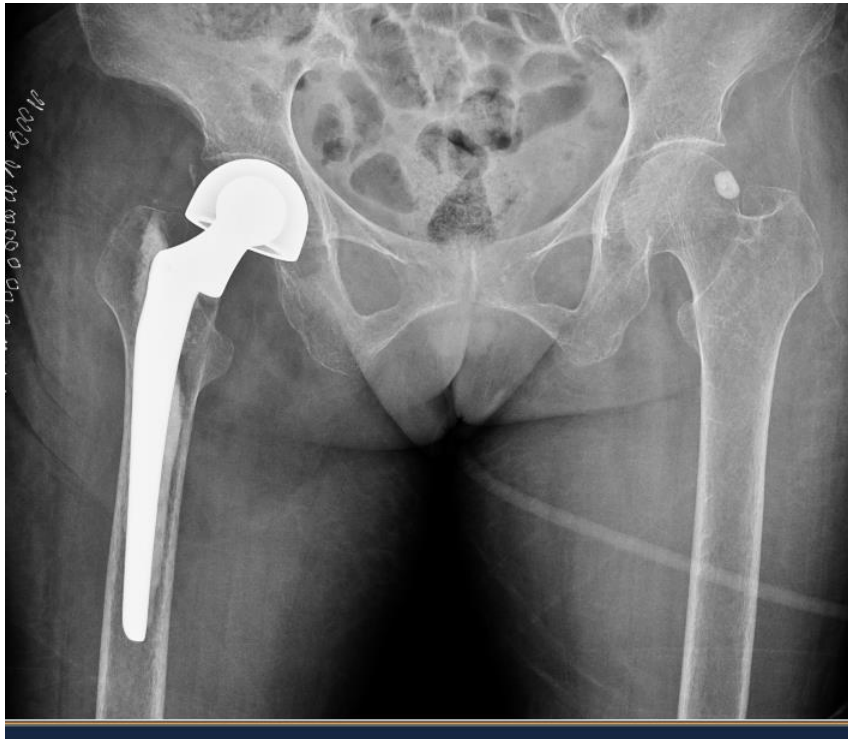Case 3



Case 4

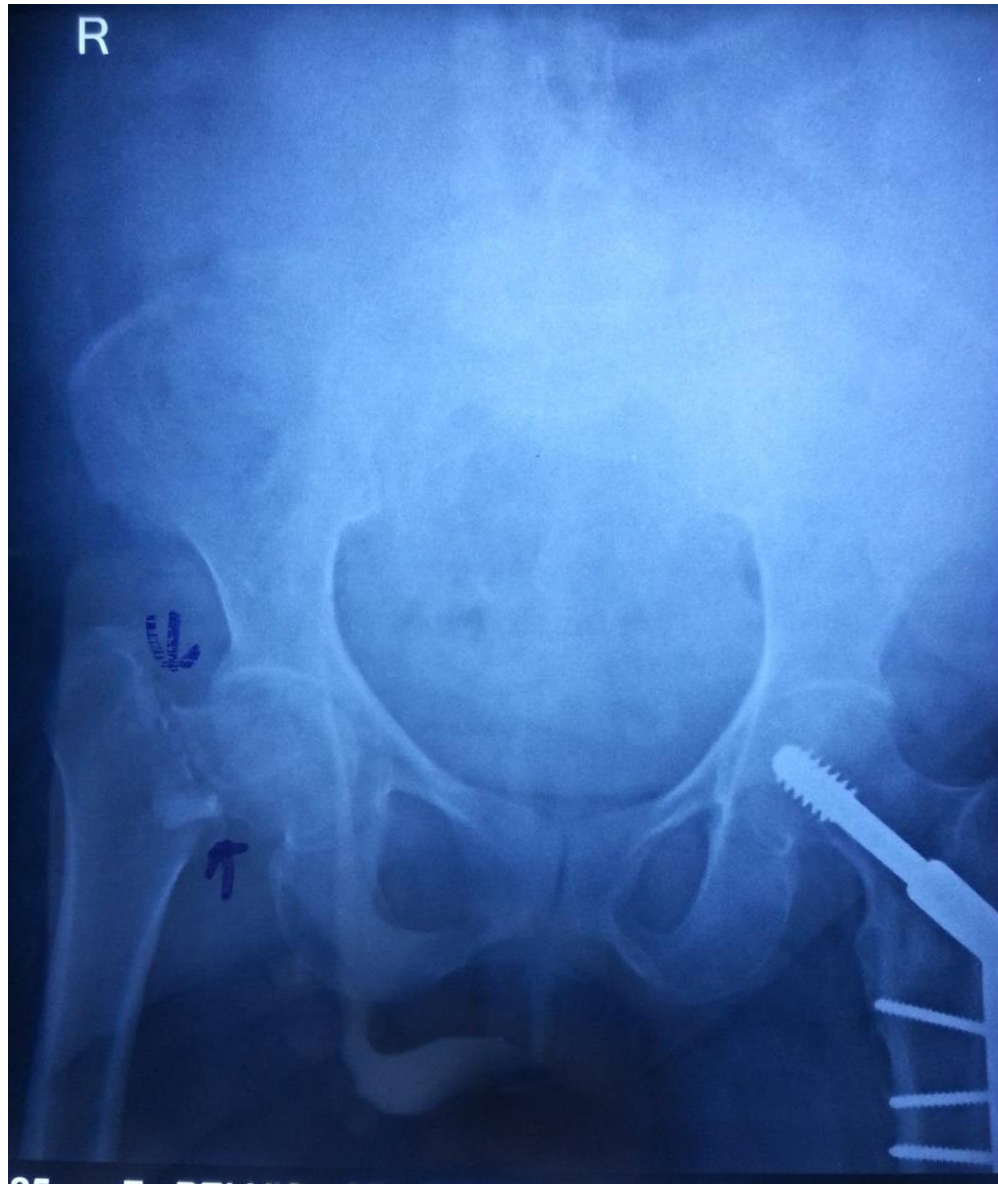
- A 91 yr female c/o pain and difficult to bear weight on her Rt lower limb had a fall at home 15 days back was diagnosed as fracture neck of femur ,was operated with bipolar hemiarthroplasty .

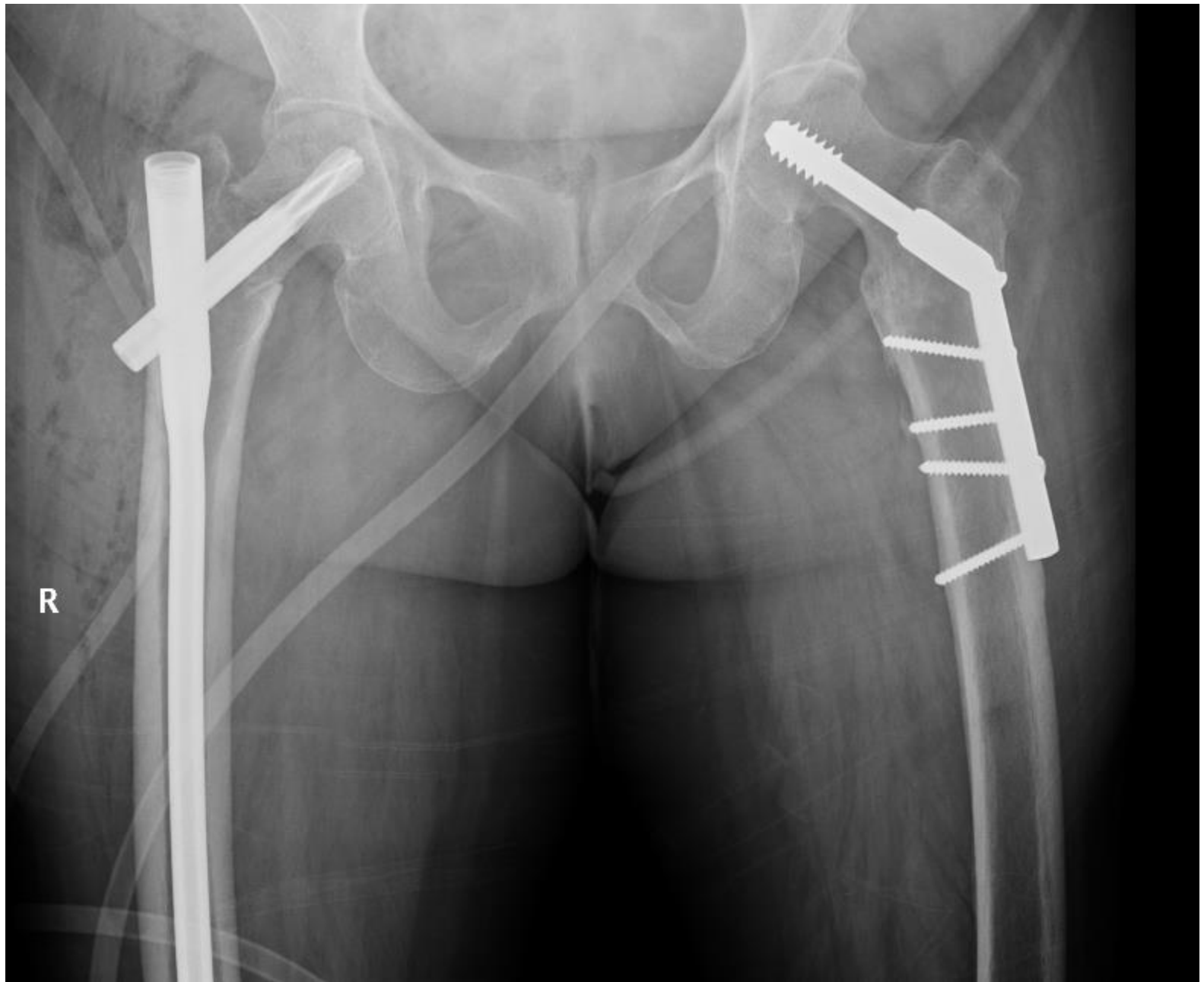


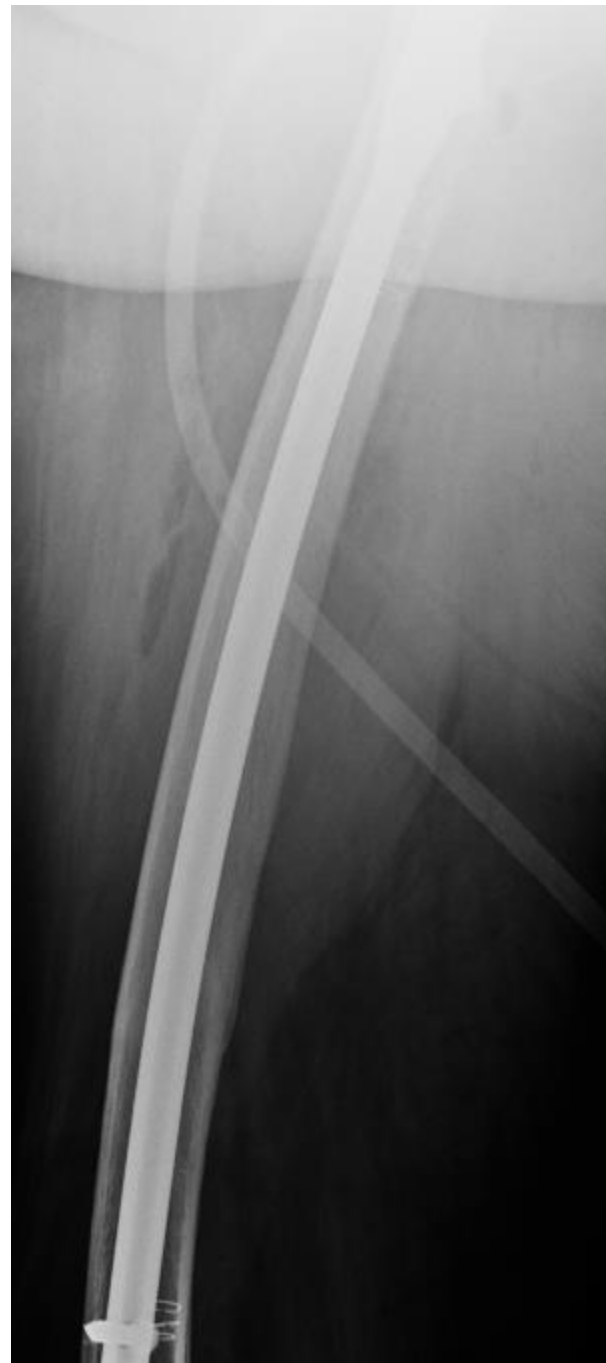
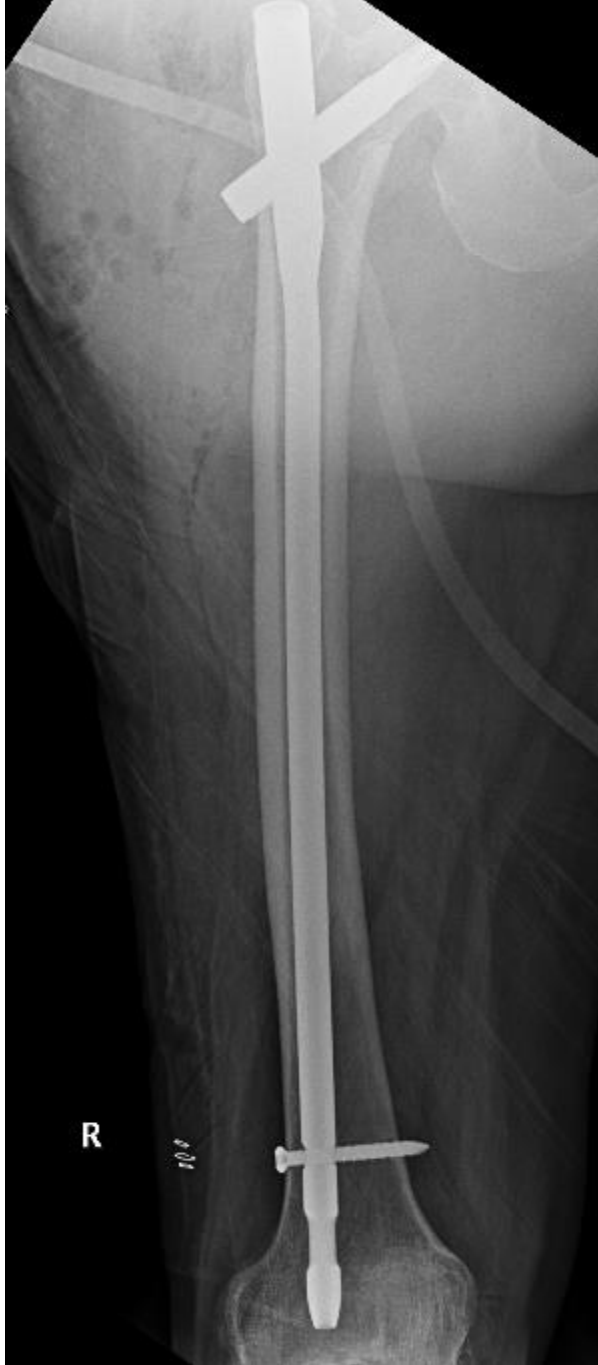Case 5

A 62 year female c/o pain in her Rt hip with h/o fall at home. left hip was operated 5 years back with DHS now was treated with PFN A 2. after the surgery she was made to walk without any support .



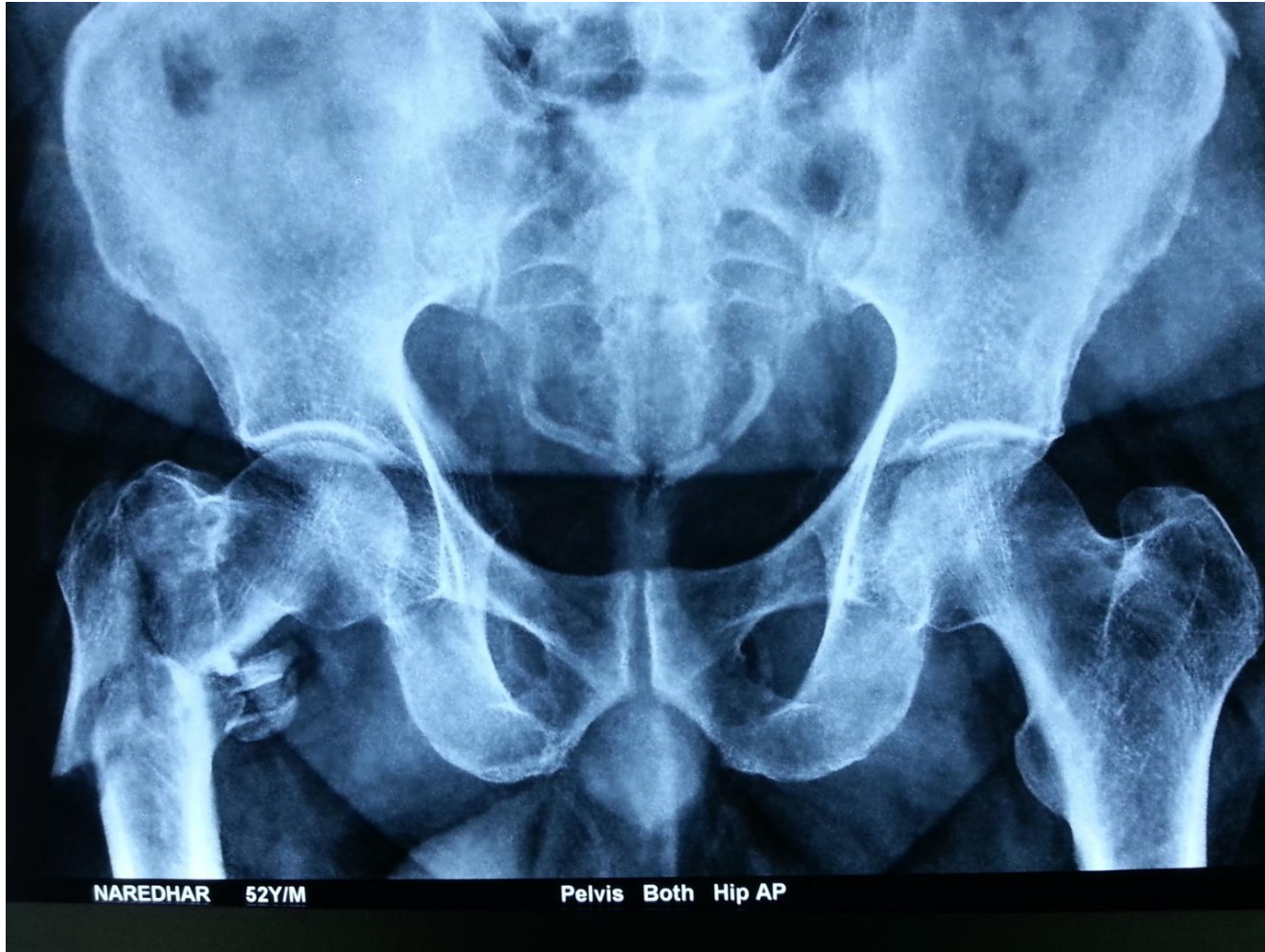



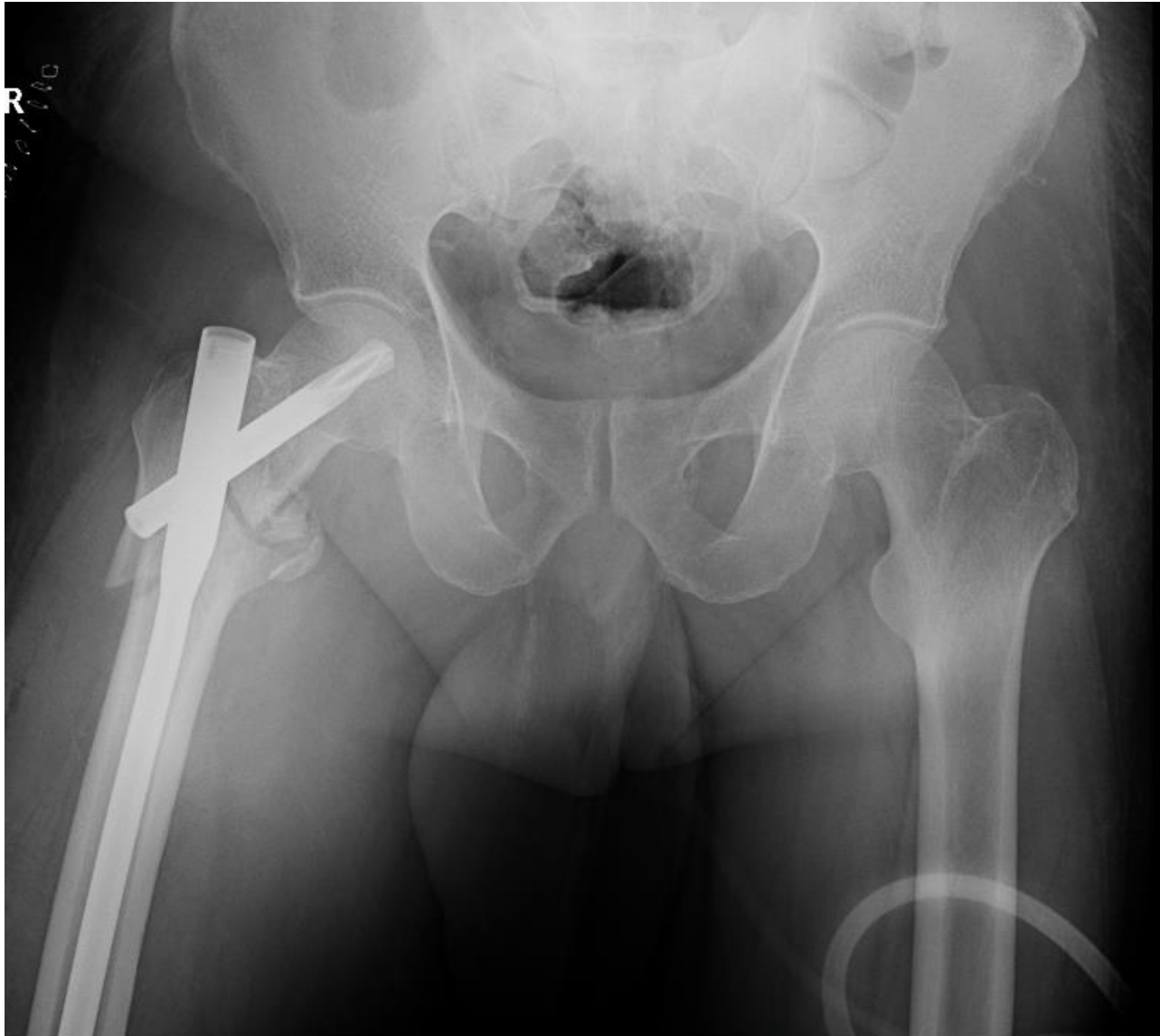CASE 6

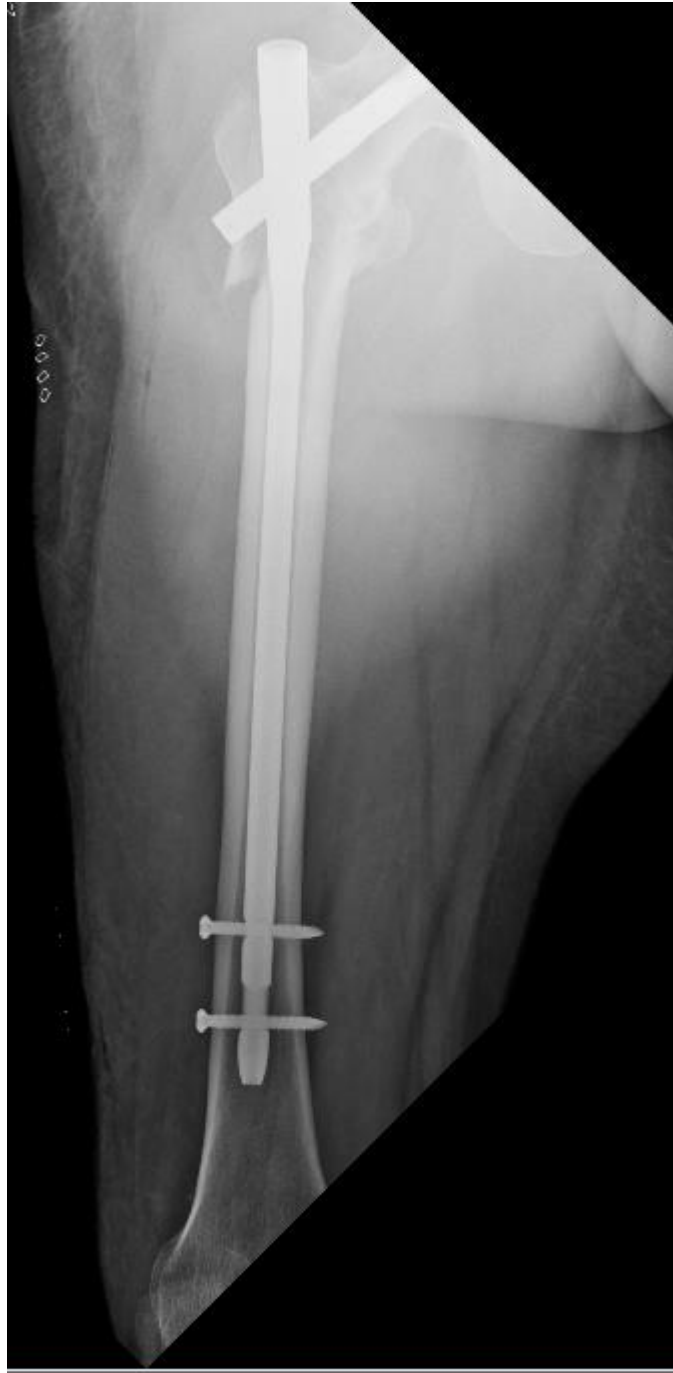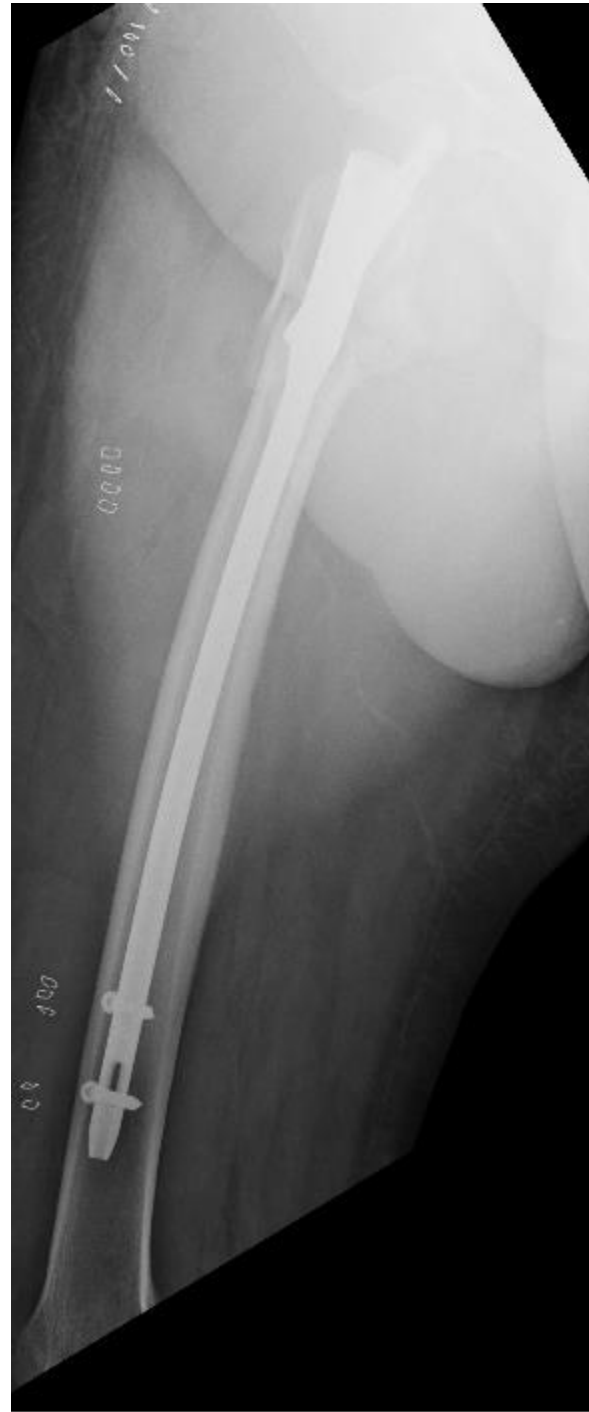51 y male c/o pain in his rt hip.with road traffic accident a very badly comminuted fracture right trochanter was operated with PFN A 2.

Case 6



Case 6

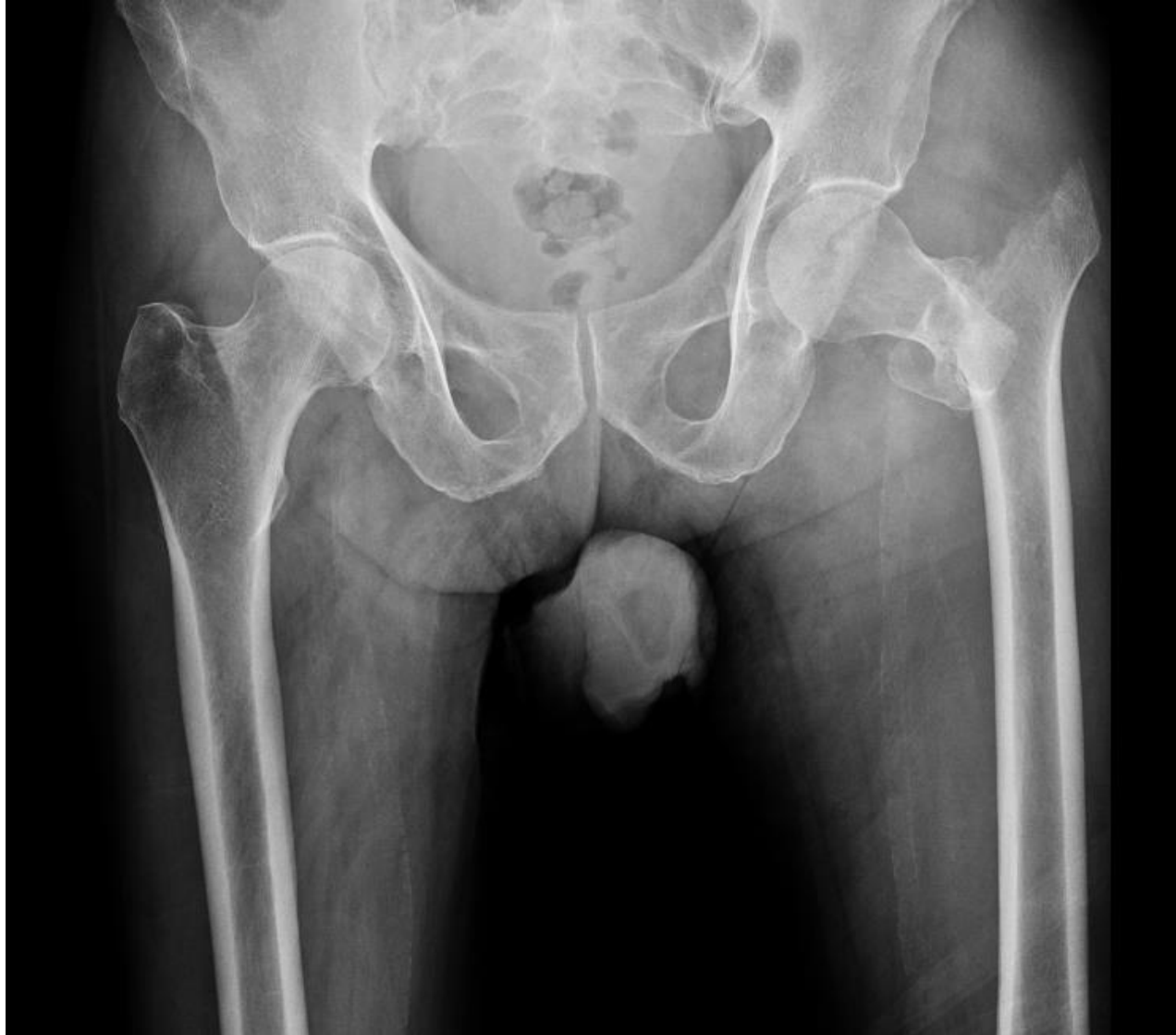



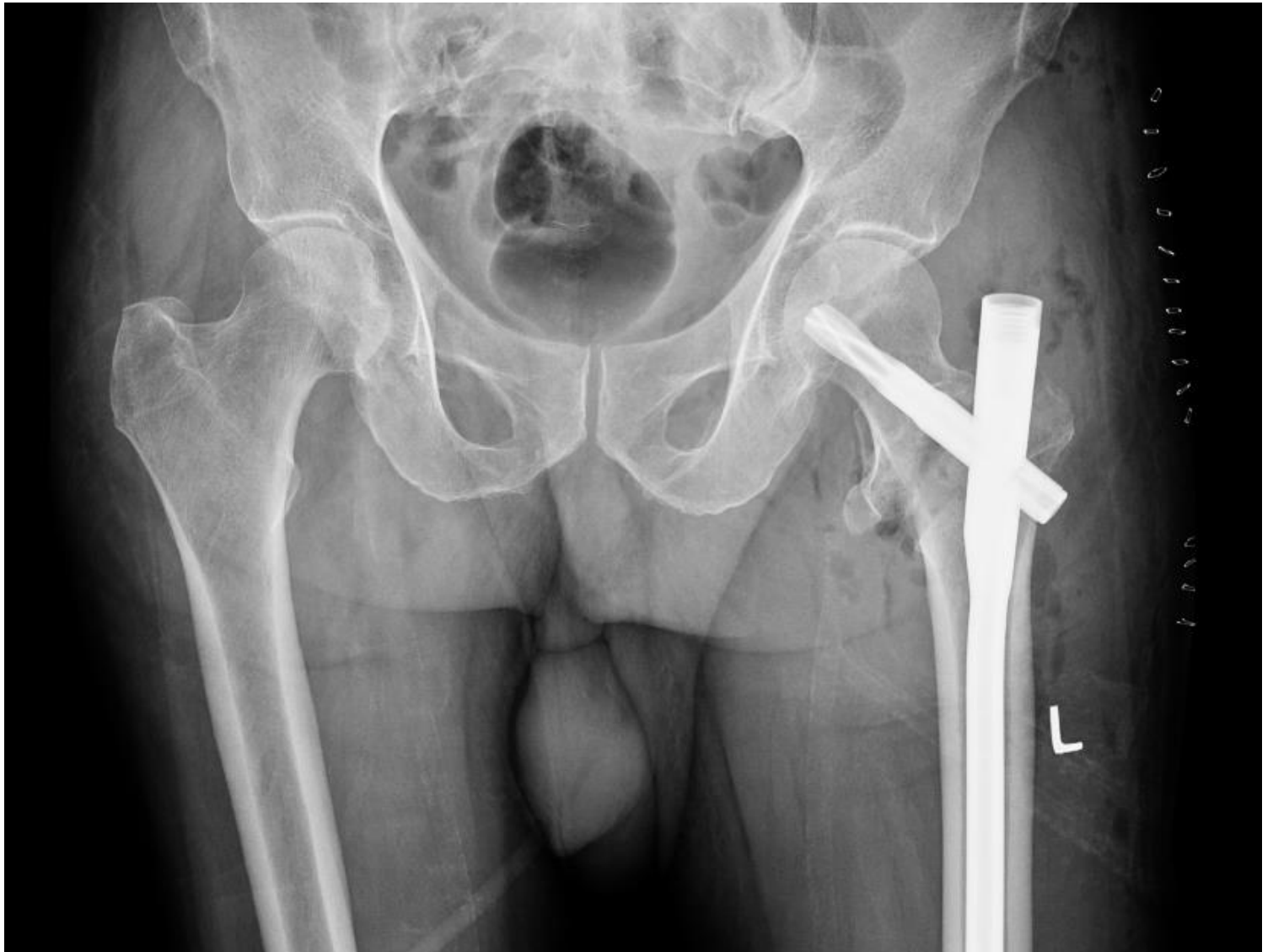CASE 7

- 75 y male c/o pain in his left hip.had a fall at home sustained fracture left trochanter was operated with PFN A 2.

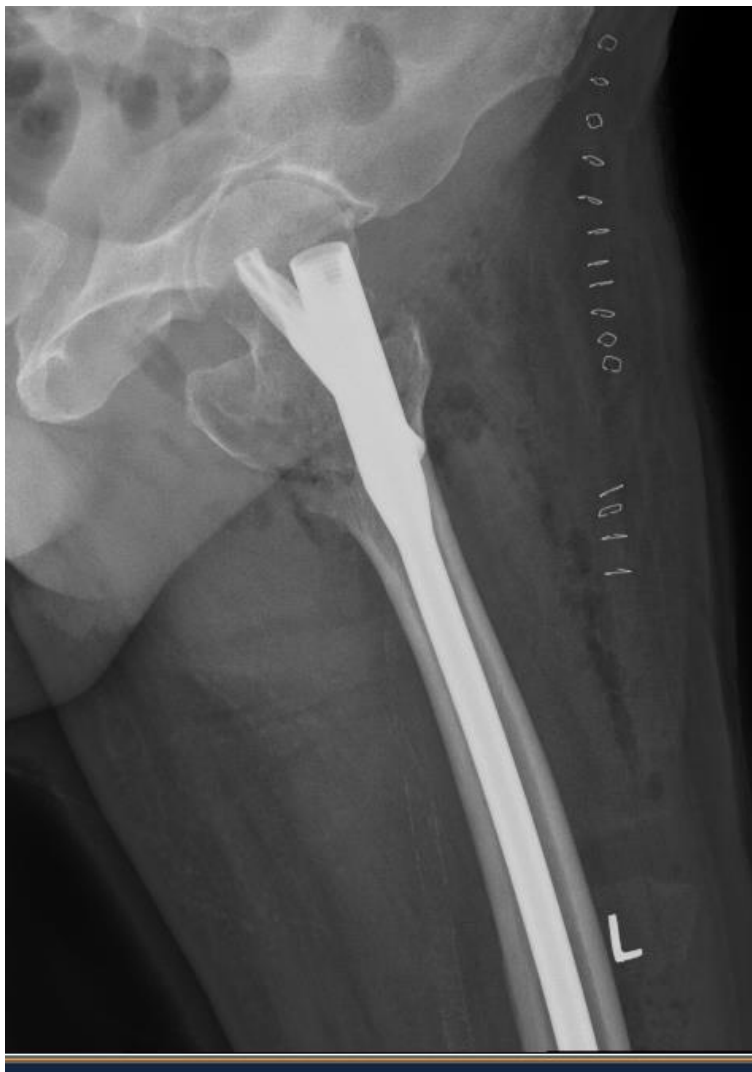CASE 7

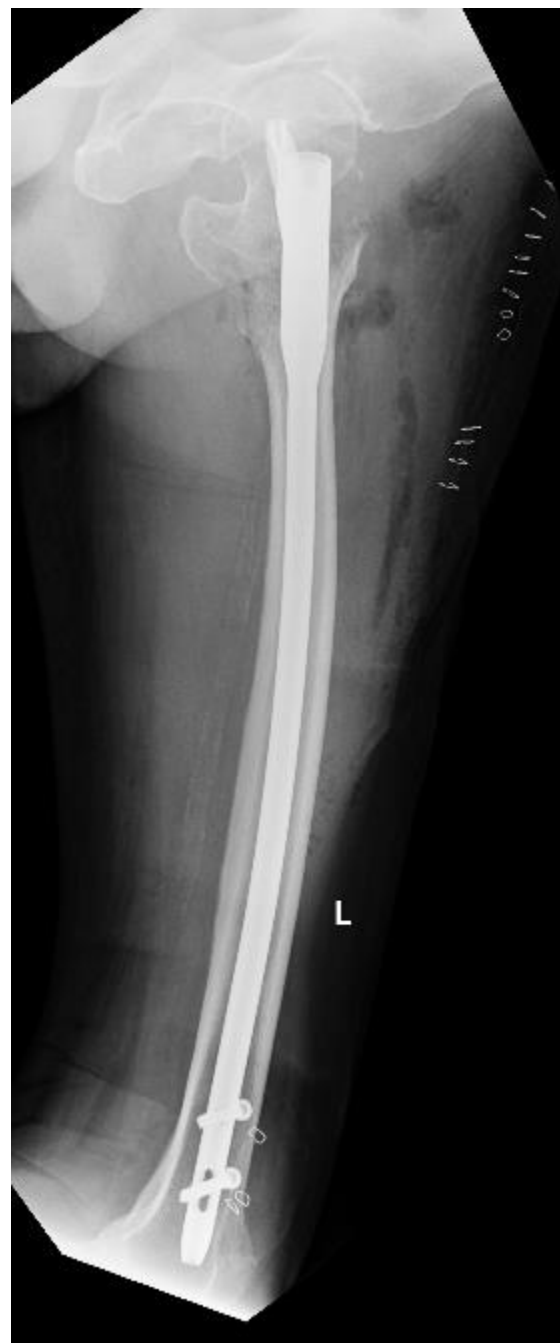
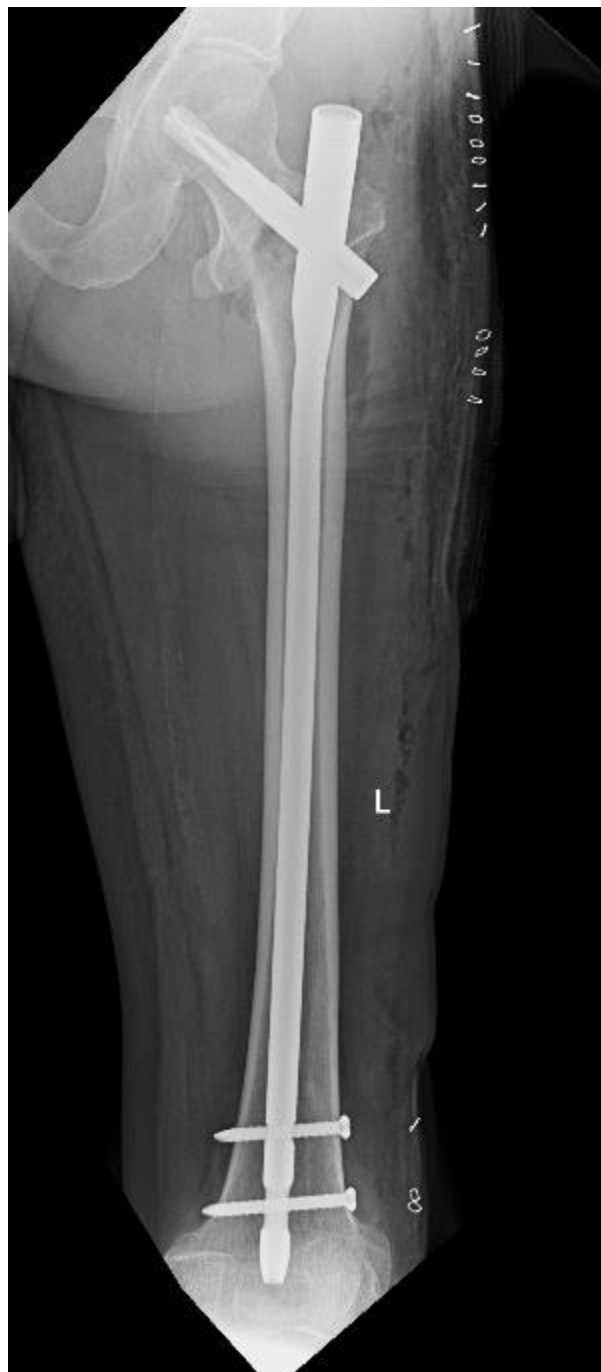
CASE 7



CASE 7

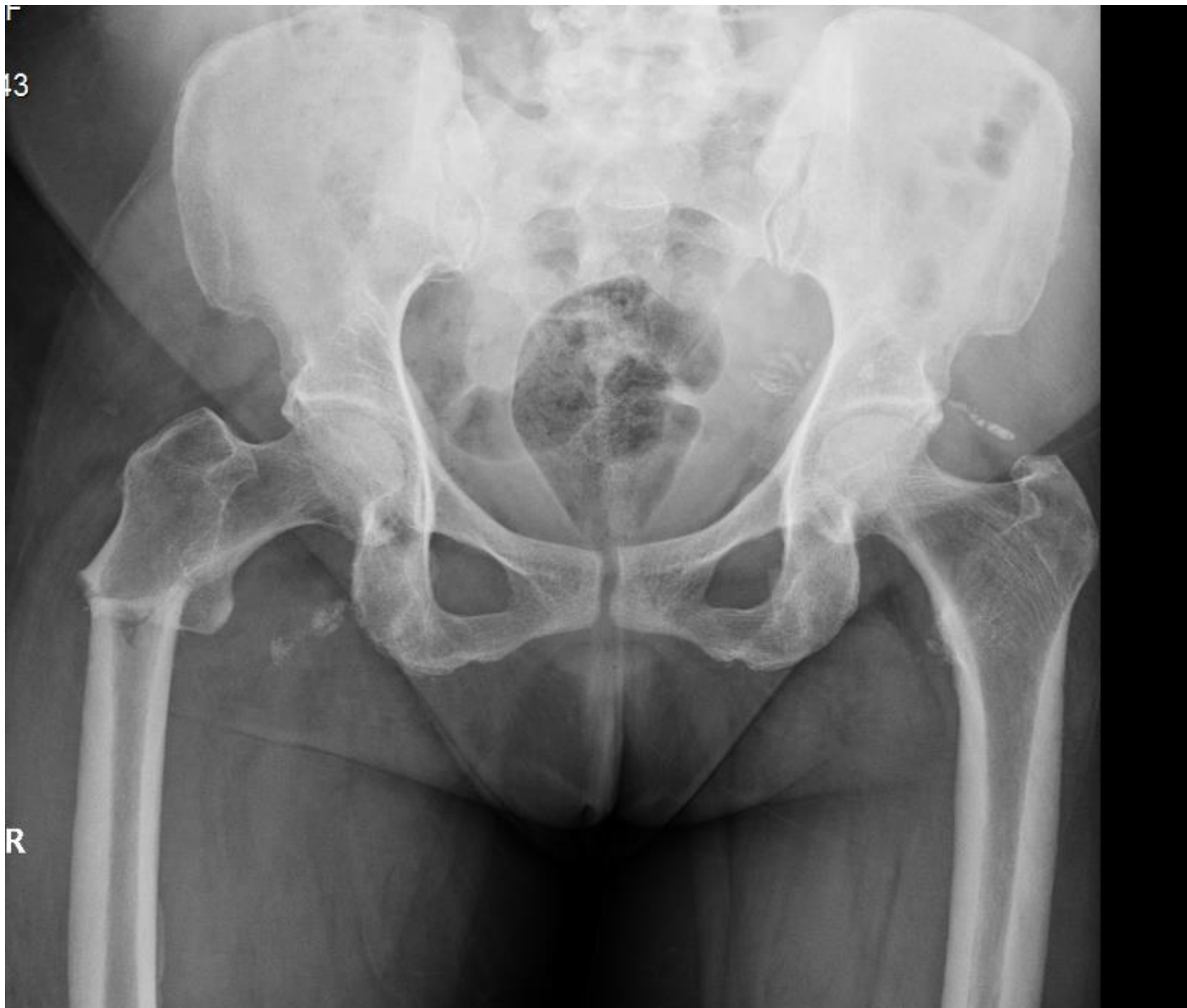



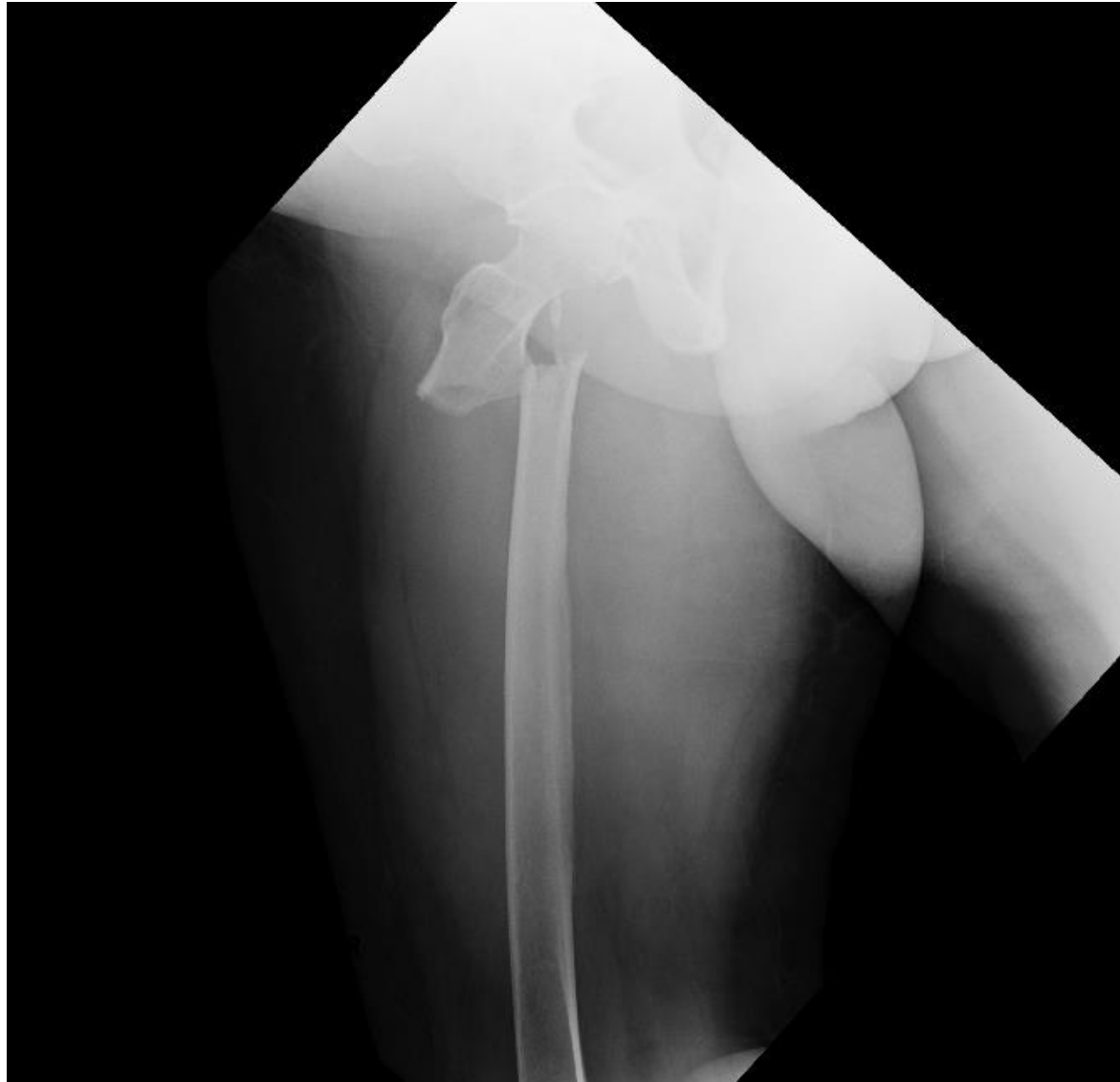CASE 8

72 y female c/o pain in her rt hip following
fall at home

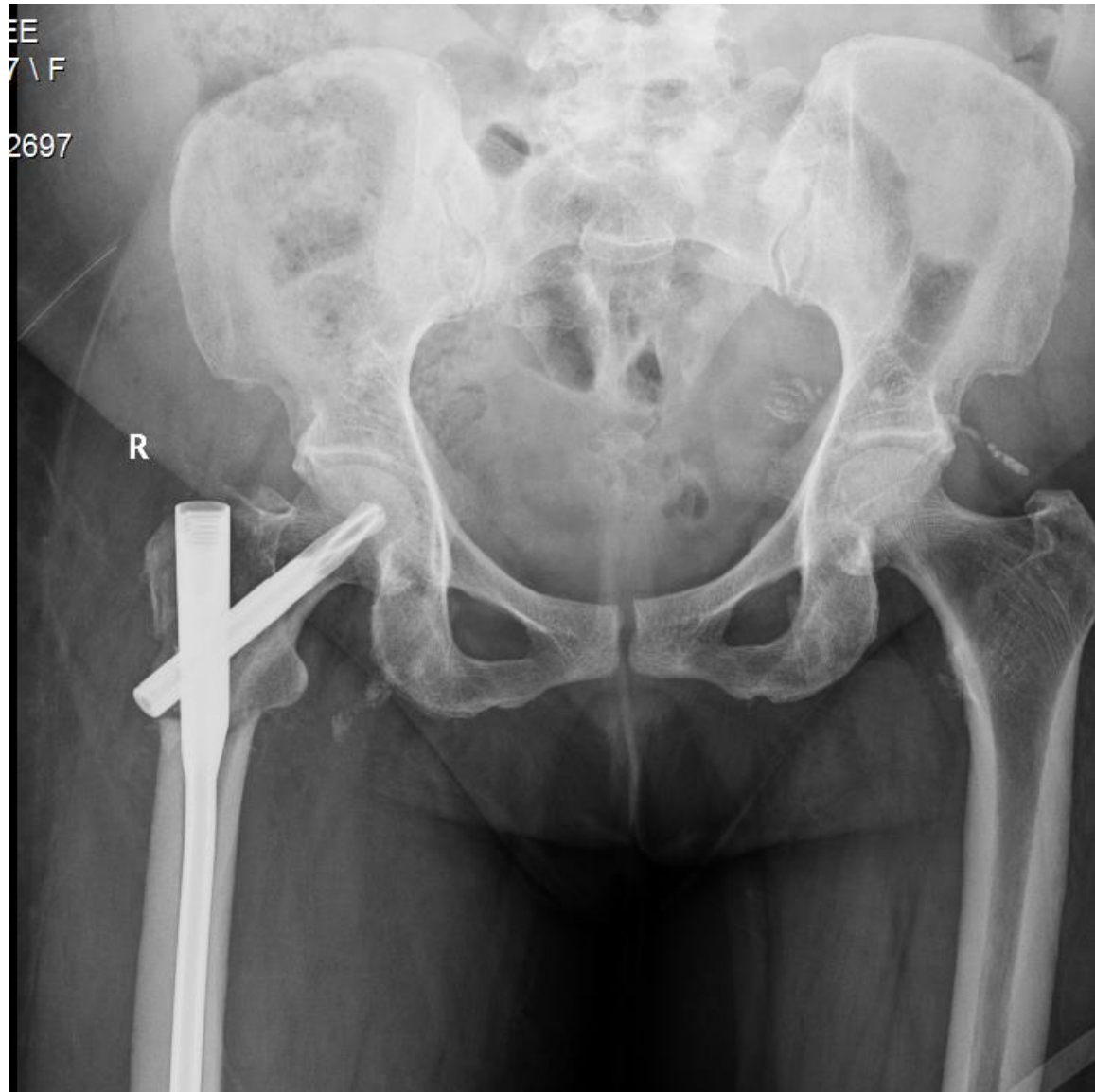CASE 8

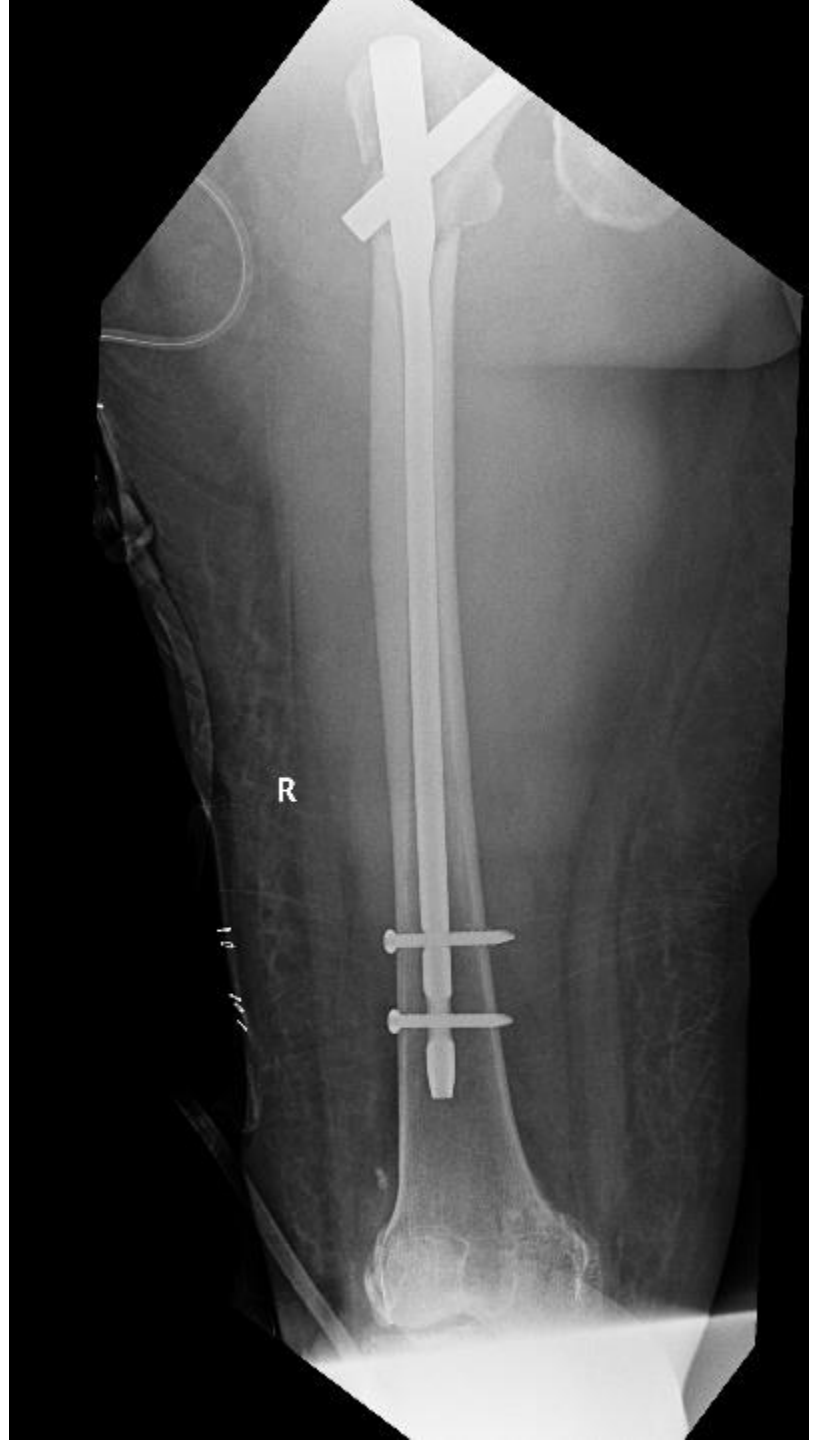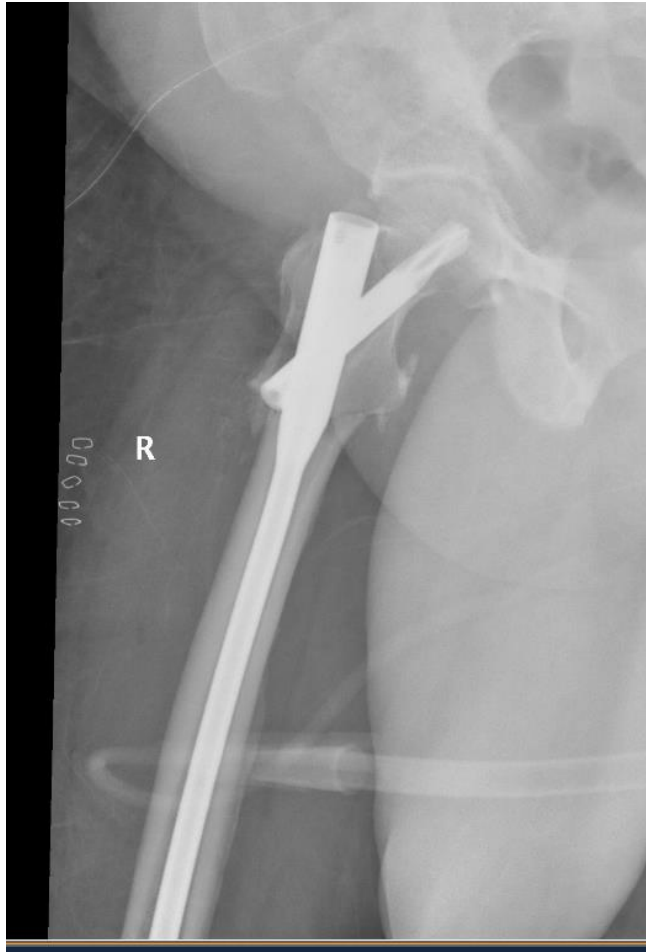


CASE 8



CASE 8

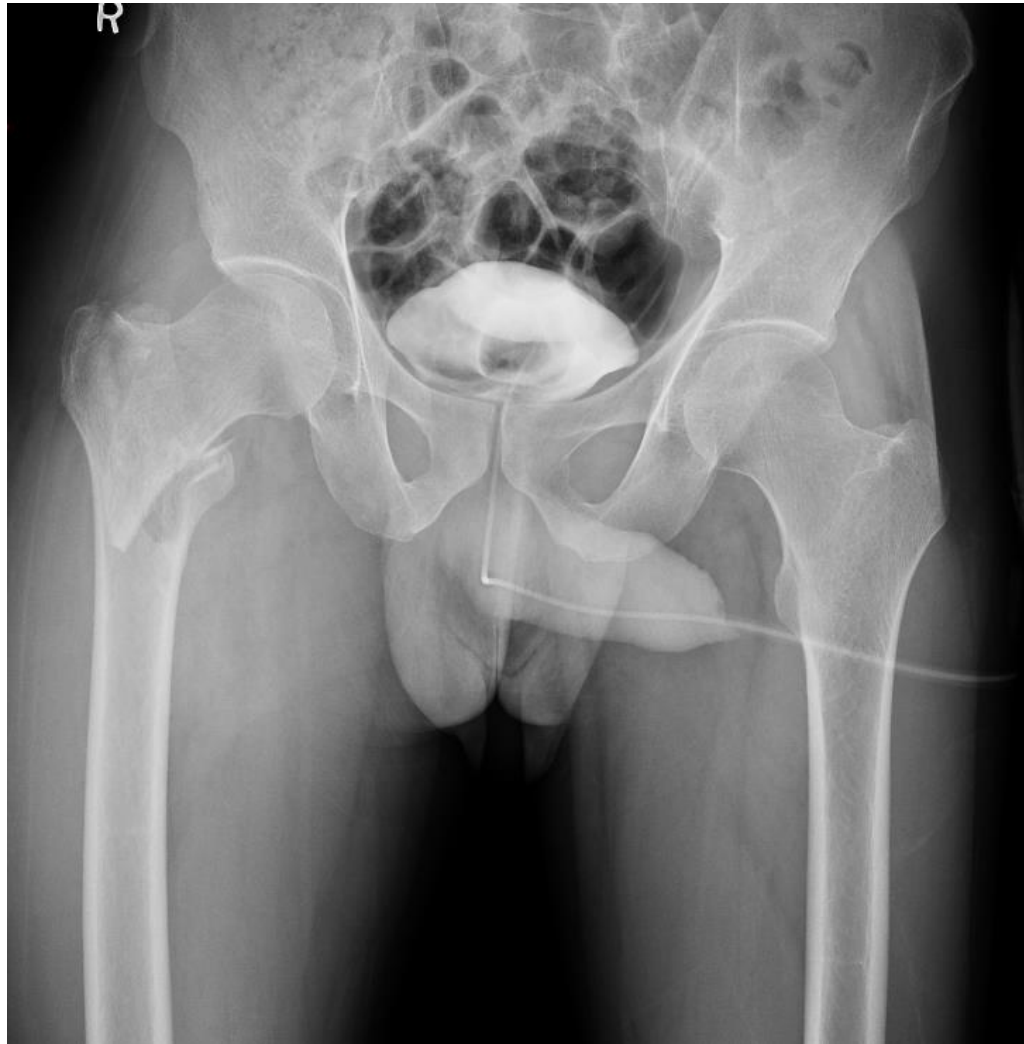



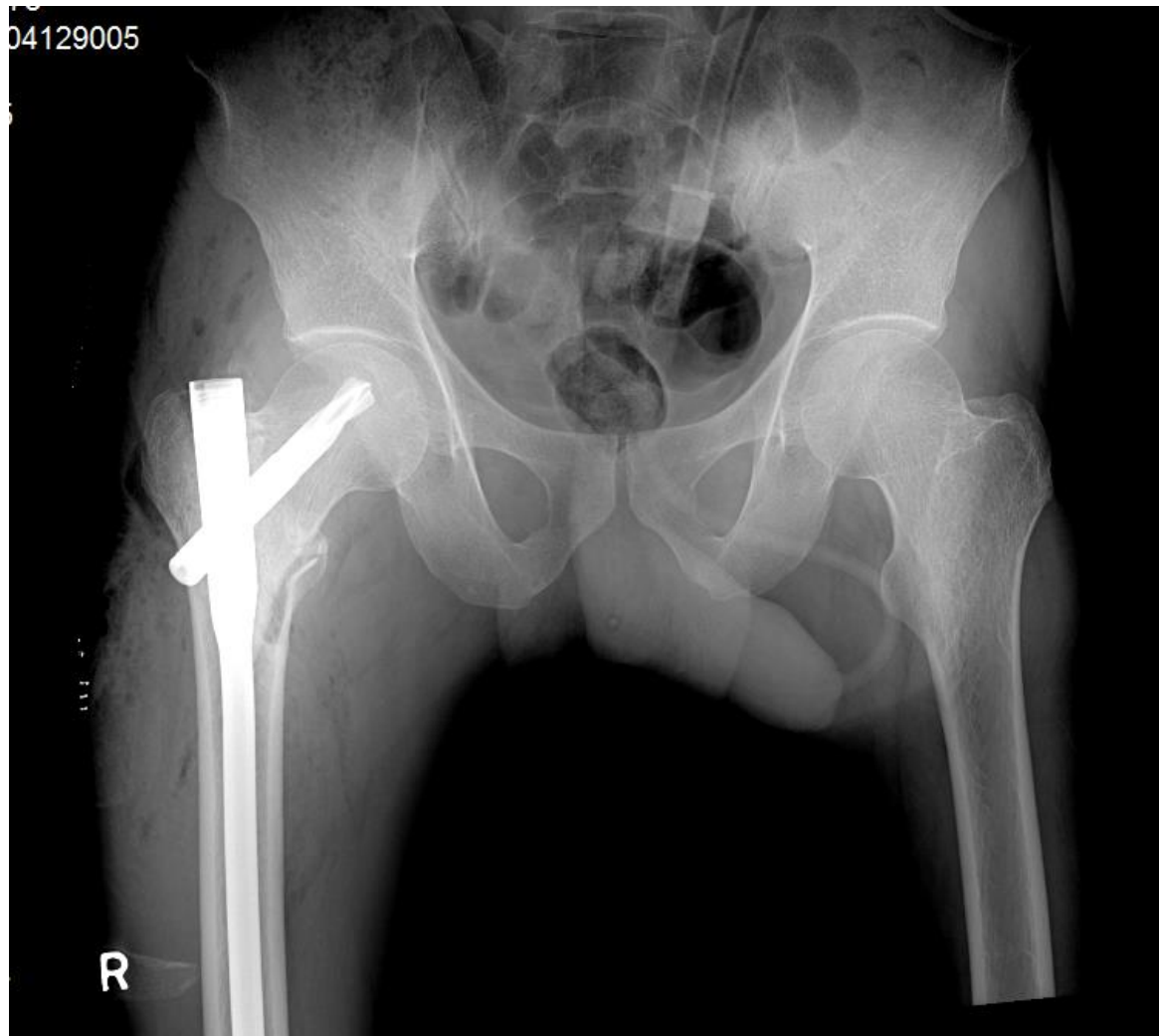
CASE 9

- 52 year male met with accident and sustained fracture of right hip was diagnosed fracture right trochanter of femur was operated with PFN A 2 was made to walk immediately after surgery

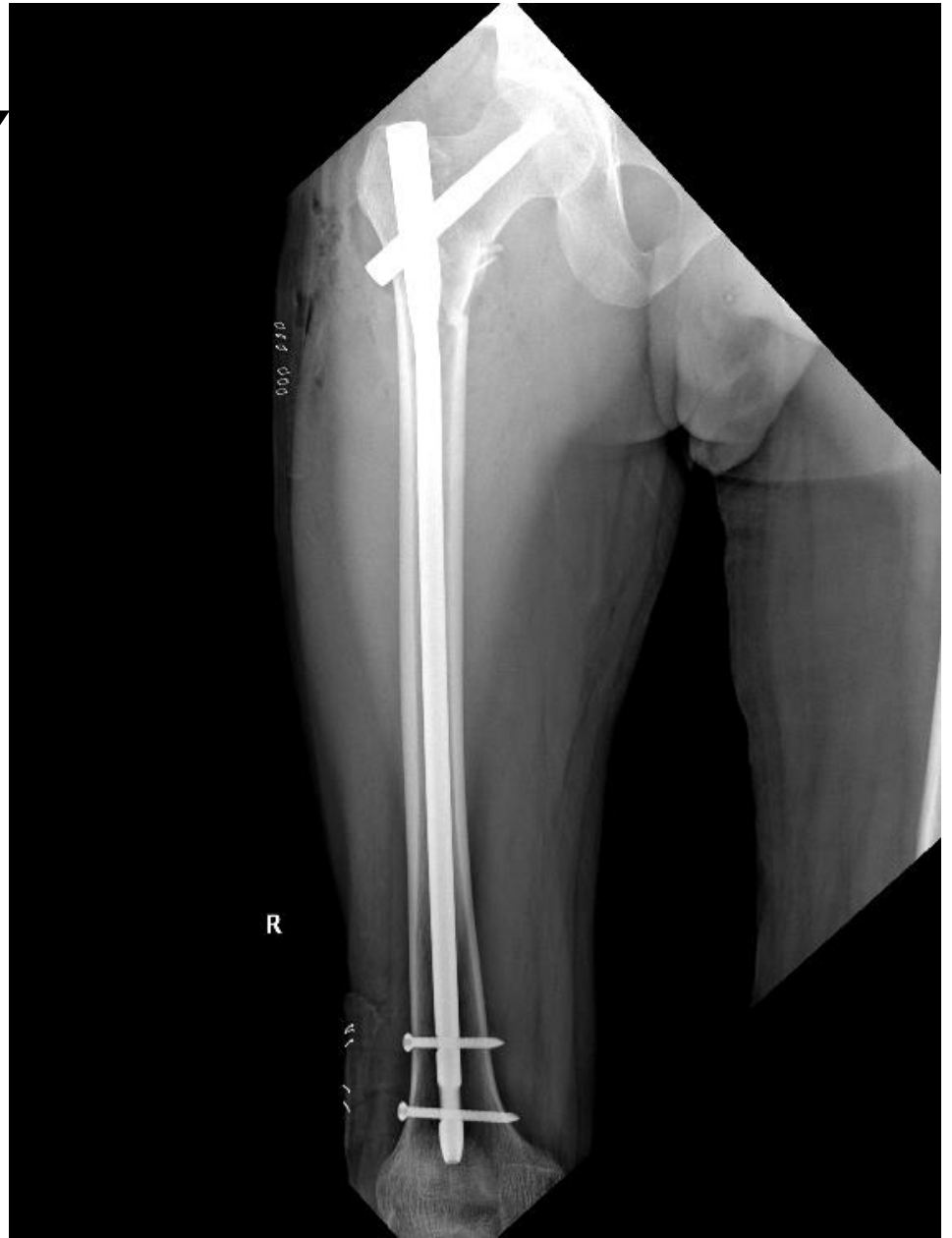CASE 9



CASE 9

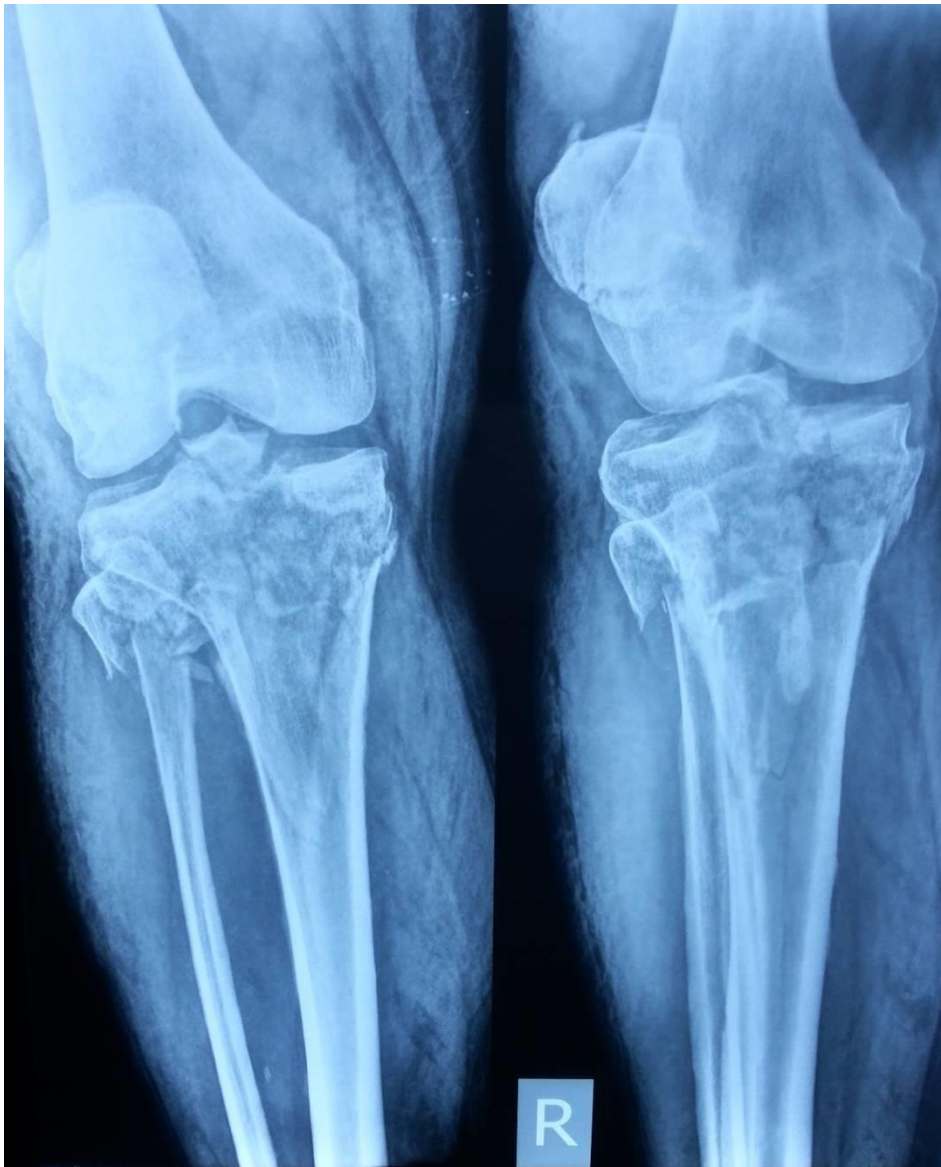


POST OP X RAY



Case 10

- 68 year male met with accident and sustained fracture of right knee was diagnosed comminuted fracture right proximal tibia of femur was operated with both column fixation of tibia with locking plates and screws .



Lower Extremities Knee AP
VENUGOPAL CHOWDARI/68Y

Lower Extremities Knee LAT

5/19/2014 4:21:32 PM



